




# The Open Ophthalmology Journal

Content list available at: <https://openophthalmologyjournal.com>



## RESEARCH ARTICLE

### Pupillary Diameter Change and Dynamics in Different Refractive Error Groups after Implantation of a Collamer Lens with a Central Hole Without Viscoelastic Agent

Ma Zicheng<sup>1</sup> and Zhu Siquan<sup>1,\*</sup>

<sup>1</sup>Department of Ophthalmology, Beijing AnZhen Hospital, Capital Medical University, Beijing 100029, China

#### Abstract:

#### Background:

To investigate the pupillary diameter and dynamics in different refractive error groups after non-viscoelastic agent-assisted implantation of a collamer lens with a central hole, so as to evaluate the effect on the pupil of this type of surgery.

#### Methods:

Consecutive patients with a range of refractive errors who underwent non-viscoelastic agent-assisted implantation of a collamer lens with a central hole (ICL V4c) were analyzed. OPD-Scan III (NIDEK Japan) was used to measure the pupillary diameter preoperatively and 1 month postoperatively. Pupillary dynamics were assessed by calculating the scotopic pupillary diameter minus the photopic pupillary diameter. All variables were measured under photopic and scotopic conditions.

#### Results:

In 53 patients (medium-low myopia group 44 eyes, 23 patients, age 33.3±1.2 years and high myopia group 60 eyes, 30 patients, age 31.7±1.5 years), the postoperative photopic pupil was significantly smaller than preoperatively in both groups, and the postoperative pupillary size was significantly larger in the high myopia group under both the photopic and scotopic conditions. Besides, the high myopia group had a significantly larger photopic-scotopic change postoperatively and greater change in the pupillary dynamics.

#### Conclusion:

Implantation of a collamer lens with a central hole without viscoelastic agent assistance affected the pupillary diameter and dynamics at 1 month postoperatively in the medium-low and high myopia groups. The group with medium and low diopters had stronger changes in pupil diameter after surgery, while the group with high diopters was more likely to be affected by changes in visual quality.

**Keywords:** Implantable collamer lens with a central hole (ICL V4c), Pupil, Pupillary dynamics, Non-viscoelastic agent-assisted implantation, lens, Refractive error.

#### Article History

Received: May 31, 2023

Revised: August 23, 2023

Accepted: August 30, 2023

## 1. INTRODUCTION

The implantable collamer lens (ICL) with a central hole (ICL V4c) (STAAR Surgical) has been proven to be a safe and effective method to correct myopia since its introduction in 2011 [1]. The newly designed central hole of 360 μm allows aqueous humor to flow without iridectomy [2], which further expands the indications of the lens.

The surgical technique of ICL implantation is also improving. The conventional implantation procedure was the

viscoelastic agent-assisted technique [3]. However, intraocular pressure (IOP) elevation sometimes seen following the use of viscoelastics is usually transient. The IOP spike is generally seen within 6 to 24 hours postoperatively. In most cases, the IOP returns to normal within 72 hours postoperatively [4]. Without the use of viscoelastic agents can avoid the impact on the intraocular pressure, so non-viscoelastic agent-assisted implantation is increasingly being used [5].

It is well known that the pupillary diameter and response are closely related to the visual quality after ICL implantation. For example, many studies have shown that the dynamic pupillary light response plays a significant role in halo

\* Address correspondence to this author at the Department of Ophthalmology, Beijing AnZhen Hospital, Capital Medical University, Beijing 100029, China; Tel: +0086 010 64456662; E-mail: [siquanzhu@qq.com](mailto:siquanzhu@qq.com)

development after conditional ICL implantation [6, 7]. Halos cause many visual complications, especially while driving at night.

At the same time, to better investigate its effects, we grouped all patients according to their diopters, so the present study was performed to investigate the changes in pupillary light response to different light intensities before and after non-viscoelastic agent-assisted ICL V4c implantation, and compare the changes in pupillary diameter in patients with different diopters.

## 2. PATIENTS AND METHODS

The study was approved by the Ethics Committee of Beijing Anzhen Hospital. All relevant tenets of the Declaration of Helsinki were followed. Written informed consent was obtained from all participants.

### 2.1. Sample

This consecutive, observational, retrospective study included 53 patients who underwent ICL V4c implantation from August 2019 to January 2021 at Beijing Anzhen Hospital in China. All patients who received an ICL met the following surgical indications: age 20-40 years, stable refractive error for at least 1 year. The exclusion criteria were: any ocular or systemic disease or anomaly that might affect the pupillary diameter or light perception, history of the use of any medications that might affect iris mechanics, and previous ocular surgery.

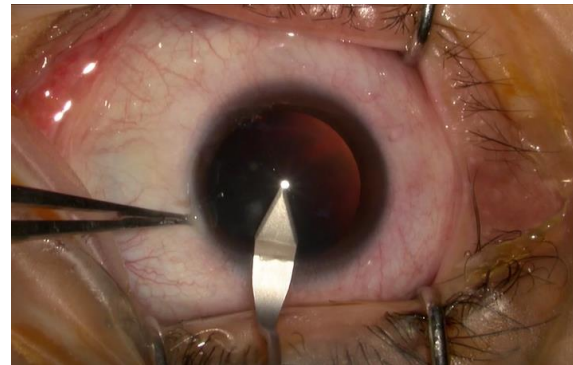
### 2.2. Evaluated Variables

All patients underwent a comprehensive ophthalmologic examination before surgery to assess the following variables: (1) uncorrected distance visual acuity, best-corrected distance visual acuity, IOP (Topcon CT-80A Japan), endothelial cell density (Topcon SP-3000P Japan), slit lamp examination and funduscopy examination (2) spherical equivalent, anterior chamber depth, and central corneal thickness with the IOLMaster 700 (ZEISS German), (3) white-to-white diameter assessed with both the IOLMaster and ultrasound biomicroscopy. The ICL power and size were determined in accordance with the manufacturer's recommendations using an online calculator. General history and medication history were also obtained.

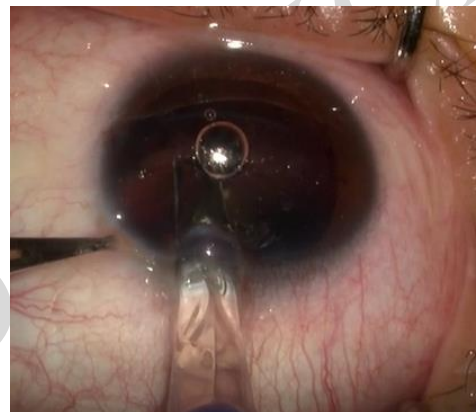### 2.3. Operation Procedure

Patients were instructed to use levofloxacin eye drops for 3 days before surgery. All surgeries were performed by one experienced surgeon (ZSQ) in the same operation room. A mydriatic agent was applied three times in 1 hour before surgery to minimize the effects of the drug acting on the pupil. An ICL V4c was inserted through a 3.0 mm clear corneal incision (Fig. 1) without sodium hyaluronate use in the anterior chamber (Fig. 2). The ICL was then adjusted to the posterior chamber by irrigation with a balanced salt solution (Fig. 3). Pupils were naturally constricted without drugs after the surgery. Tobramycin and dexamethasone eye drops and recombinant bovine basic fibroblast growth factor eye drops were administered postoperatively three times daily for 1 week,

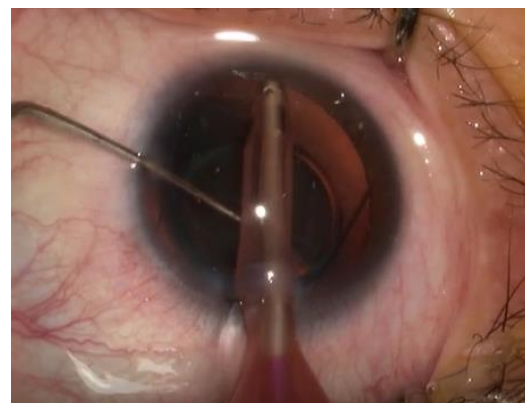
then replaced by bromfenac sodium hydrate ophthalmic solution twice daily for 2 weeks.



**Fig. (1).** A 3.0 mm clear corneal incision with good tightness was made, which can maintain the anterior chamber depth without the aid of a viscoelastic agent.



**Fig. (2).** An ICL V4c was inserted into the anterior chamber without a viscoelastic agent.



**Fig. (3).** The ICL was then adjusted to the posterior chamber by irrigation with a balanced salt solution. Positioning the ICL lens with a 1/A handle allows for more uniform force.

### 2.4. Measurements of Pupillary Diameter and Pupillary Dynamics

OPD Scan was used to measure the pupillary diameter before and 1 month after ICL implantation. All examinations were performed by one clinician (WH) in the same room between 08:00 and 11:00 in the morning. Measurements were

performed after 15 minutes of light adaption. The average pupillary diameters under two standardized illumination conditions were recorded after at least three consecutive measurements at each illumination level. The pupillary dynamics were assessed by subtracting the difference between the scotopic and photopic pupils (scotopic pupillary diameter minus the photopic pupillary diameter).

### 2.5. Statistical Analyses

All results were analyzed using the Statistical Package for the Social Sciences version 22.0 (IBM). Data are expressed as mean±standard deviation. The appropriate statistical analysis method was selected based on whether the data were normally distributed and had homogeneity of variance. P values <0.05 were considered statistically significant.

All patients were separated based on their refractive error into the medium-low myopia group (diopter -6D to 0D) or the high myopia group (diopter < -6D). The pre- and postoperative pupillary diameters in the photopic and scotopic conditions were compared between and within these two groups.

### 3. RESULTS

A total of 53 patients (104 eyes) were included. All patients were separated into medium-low myopia group and high myopia group in accordance with their preoperative spherical equivalent measurements. The medium-low myopia

group comprised 44 eyes (23 patients, age 33.3±1.2 years, six men), while the high myopia group comprised 60 eyes (30 patients, age 31.7±1.5 years, five men). The patient and ocular characteristics are shown in Table 1. There were no significant differences between groups in age (P=0.59) and sex (P=0.31). Intragroup comparisons showed that the postoperative photopic pupil was significantly smaller than the preoperative one in both the medium-low myopia group (P=0.02) and the high myopia group (P=0.003). However, there was no significant change in the scotopic pupillary size (Table 2). Table 3 demonstrates that the preoperative pupillary size did not significantly differ between the two groups under both the photopic and scotopic conditions, but the postoperative pupillary size was significantly larger in the high myopia group than the medium-low myopia group under both the photopic and scotopic conditions. There is a decreasing tendency of pupil size under both photopic and scotopic conditions in medium-low myopia group after the ICL implantation, but an increasing tendency of scotopic pupil size in the high myopia group which is opposite to the photopic condition (Fig. 4). Table 4 shows the postoperative change in pupillary dynamics in the two groups; the high myopia group had a significantly larger change in pupillary dynamics postoperatively (1.59±0.53) versus preoperatively (1.39±0.44). In the high myopia group, the change in pupil diameter after the operation is more significantly correlated with that before the operation (Fig. 5).

**Table 1. The patient and ocular characteristics.**

		Medium-low Myopia Group	High Myopia Group	P
N(eyes, patients)		44, 23	60, 30	-
Men, Female		6, 17	5, 25	0.31 Chi-Square Tests *
Age(yr)		33.3±1.2	31.7±1.5	0.59 Mann-Whitney Test *
spherical equivalent refraction(D)		-4.76±0.17(-1.75 to -6.00)	-10.12±0.33(-6.50 to -17.50)	-
IOP (mmHg)	Before	15.98±0.30	15.98±0.23	-
	after	15.46±0.32	15.45±0.29	
		P=0.27 Wilcoxon Signed Ranks Test*	P=0.05 Wilcoxon Signed Ranks Test*	-

Note: 1. Data are expressed as mean±standard deviation (SD).

\* The suitable statistical analysis method is selected according to whether the data are normally distributed and have homogeneity of variance.

**Table 2. Scotopic pupillary size.**

Group		Pupile Size		P
		before	after	
medium-low myopia group	Photopic condition	4.16±0.09[3.12, 6.23]	3.99±0.10[3.28, 7.09]	0.02 T-Test*
	scotopic condition	5.63±0.13[3.92, 7.31]	5.48±0.12[4.09, 7.69]	0.06 Wilcoxon Signed Ranks Test*
high myopia	Photopic condition	4.42±0.10[3.26, 7.51]	4.27±0.10[3.24, 6.56]	0.003 Wilcoxon Signed Ranks Test*
	scotopic condition	5.81±0.84[4.30, 8.19]	5.86±0.89[4.34, 7.88]	0.32 T-Test*

Note: 1. Data are expressed as mean±standard deviation (SD).

\* The suitable statistical analysis method is selected according to whether the data are normally distributed and have homogeneity of variance.

**Table 3. The preoperative pupillary size did not significantly differ between the two groups under both the photopic and scotopic conditions.**

Pupil Size		Medium-low Myopia Group	High Myopia	P
Before	Photopic condition	4.16±0.09[3.12, 6.23]	4.42±0.10[3.26, 7.51]	0.13 Mann-Whitney Test*
	scotopic condition	5.63±0.13[3.92, 7.31]	5.81±0.11[4.30, 8.19]	0.32 ANOVA*
After	Photopic condition	3.99±0.10[3.28, 7.09]	4.27±0.10[3.24, 6.56]	0.04 Mann-Whitney Test*
	scotopic condition	5.48±0.12[4.09, 7.69]	5.86±0.11[4.34, 7.88]	0.03 ANOVA*

Note: 1. Data are expressed as mean±standard deviation (SD).

\* The suitable statistical analysis method is selected according to whether the data are normally distributed and have homogeneity of variance.

**Table 4. The postoperative change in pupillary dynamics in the two groups; the high myopia group had a significantly larger change in pupillary dynamics postoperatively (1.59±0.53) versus preoperatively (1.39±0.44).**

Pupil Dynamics	Medium-low Myopia Group	High Myopia	P
Before	1.47±0.10	1.39±0.44	0.76 Mann-Whitney Test*
After	1.48±0.09	1.59±0.53	0.47 Mann-Whitney Test*
P	0.9 T-Test*	0.002 T-Test*	-

Note: 1. Data are expressed as mean±standard deviation (SD).

\* The suitable statistical analysis method is selected according to whether the data are normally distributed and have homogeneity of variance.

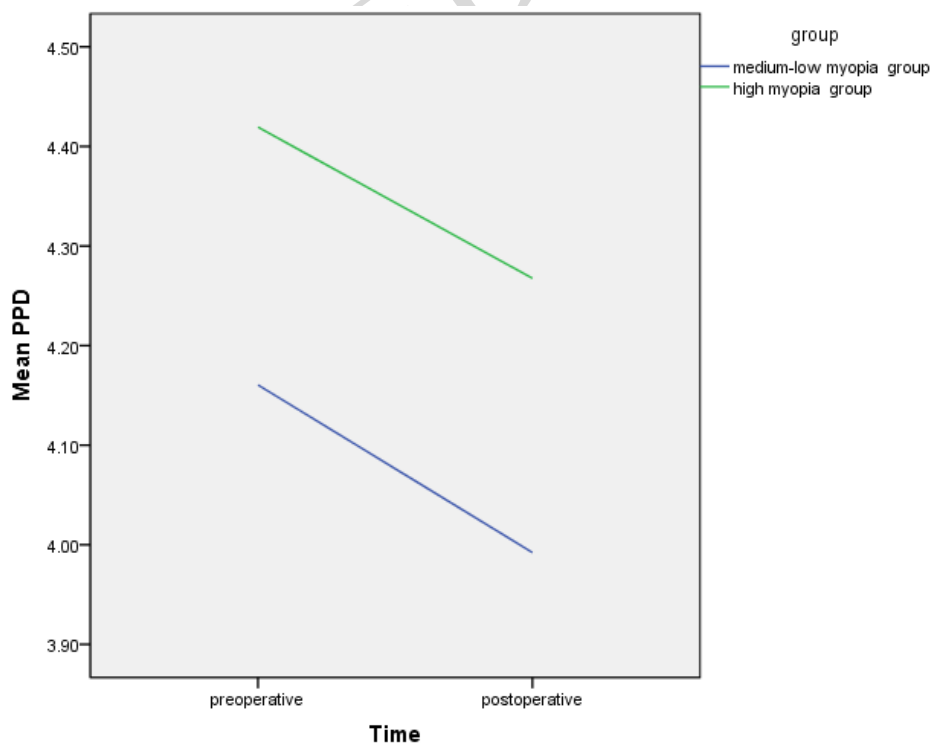


Fig. 4 contd.....

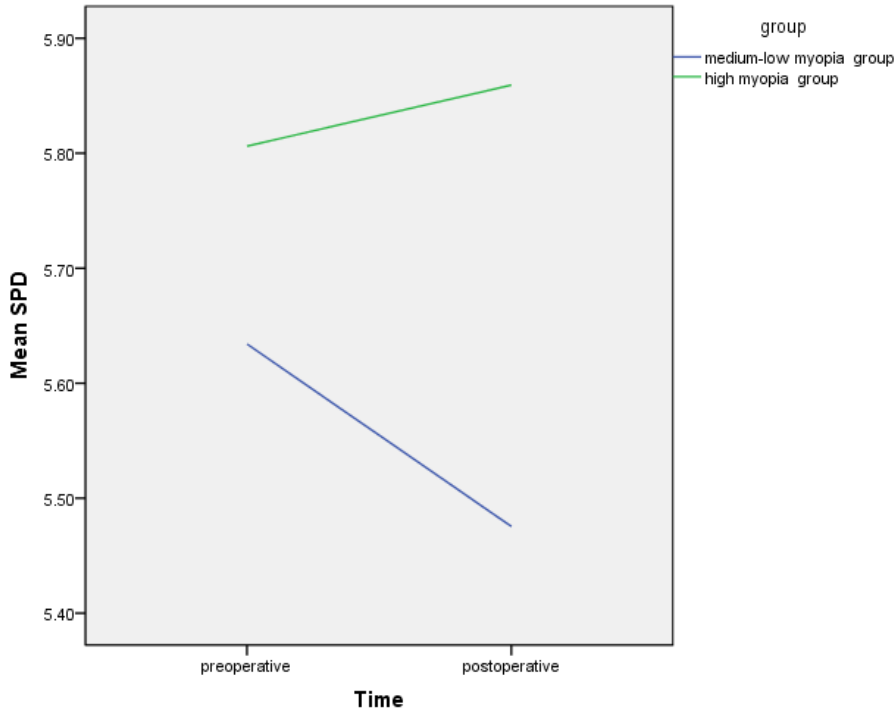


Fig. (4). Linear graph of photopic pupil diameter (PPD) and scotopic pupil diameter (SPD) change in the two groups.

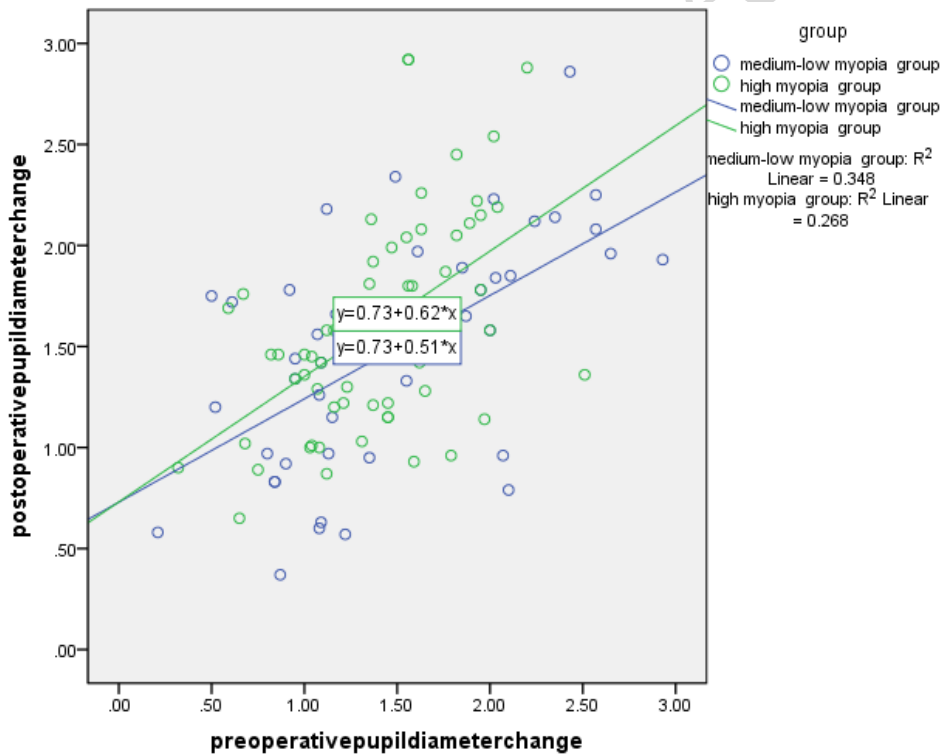


Fig. (5). Scatter plot and Linear correlation fit line of pre-and postoperative pupil size change.

4. DISCUSSION

Viscoelastic agents are widely used in ICL implantation to maintain the anterior chamber and protect the corneal endothelium functions [8, 9]. However, viscoelastic agent residue may increase the postoperative IOP due to obstruction

of the trabecular meshwork and the canal of Schlemm [10]. Niruthisard *et al.* [11] reported one patient in whom ICL implantation resulted in a fixed dilated pupil, which was thought to be related to the viscoelastic agent residue. Miao *et al.* [9] proposed a one-step technique for ICL V4c implantation

in which a small amount of viscoelastic surgical agent is used to adjust the haptic resting in the anterior chamber. However, although the IOP of all eyes decreased to baseline value at 1 day postoperatively with routine postoperative medication, four eyes had an IOP of greater than 30 mm Hg (maximum 35 mm Hg) and required corneal paracentesis 3 hours postoperatively.

In our study, the non-viscoelastic agent implantation method was adopted for ICL implantation, and the creation of an incision with good tightness was an important step. The intraoperative ICL position was adjusted underwater flow surrounded by a balanced salt solution, which not only maintained the anterior chamber space but also avoided the adverse effects caused by incomplete viscoelastic agent removal. None of the patients had an IOP of more than 21 mmHg on reexamination performed 1 day after surgery.

The pupillary changes in our study (decreased pupillary diameter after surgery) are consistent with most previous study findings. Keuch *et al.* [7, 11] used a pupillograph to assess pupillary constriction after the implantation of an ICL without a central port (model V4) and found that the pupillary diameter was significantly smaller at 2 weeks postoperatively than before surgery ( $P < 0.01$ ). Lim *et al.* [12] used a WaveScan aberrometer to evaluate the pupillary size before and 6 months after surgery under mesopic conditions (50 lx) and found a significant decrease in 64% of eyes, an increase in 20%, and

no change in 16%. However, other studies have reported different results. Gonzalez-Lopez *et al.* [13] used Fourier-domain anterior segment optical coherence tomography to perform dynamic pupillometry under photopic and scotopic conditions before and 4 months after surgery. Their results showed the mean pupillary diameter at 4 months postoperatively was larger than the mean pupillary diameter before surgery, under both photopic and scotopic conditions. Zhu *et al.* [14] investigated the pupillary diameter change after ICL implantation in highly myopic eyes and found no changes in the high-myopia group but a significant decrease under all illumination conditions in the super-high-myopia group at 1 and 3 months postoperatively. Although our study did not distinguish between high-myopia and super-high-myopia, this differs from the significant decrease in pupillary size under the photopic condition found in the high myopia group in our study. This intergroup difference may be due to the routine postoperative constriction using 0.01% (w/v) acetylcholine applied by Zhu *et al.*

There are few reports on the pupillary dynamic changes after ICL implantation. Our study is the first to compare the pupillary diameter changes under photopic and scotopic conditions to evaluate the pupillary dynamics in different diopter groups. Totsuka *et al.* [15] assessed the pupillary light reflex after ICL implantation in patients with diopter values ranging from -3.25D to -11.80D using the infrared pupillometer Irisorder C7364 (Hamamatsu Photonics) but found no significant change in pupillary dynamics at 6 months after implantation. Kato *et al.* [16] used anterior segment optical coherence tomography to examine dynamic pupillary changes under photopic and scotopic conditions and found that the pupillary size was significantly smaller during accommodation ( $3.88 \pm 0.64$  vs.  $4.10 \pm 0.61$  mm,  $P < 0.001$ ).

These discrepancies between studies may be due to variations in surgical methods, grouping methods, and observation times.

There is no clear theory as to why pupil activity is affected with viscoelastic-free use, and this experiment speculates that it may have something to do with factors such as whether ICL lens implantation partially reduces the posterior chamber space, thereby affecting atrial water circulation, or whether the crystal loops in the ciliary sulcus may partially affect the root of the iris, thereby affecting pupillary light-reflective dynamics, or even whether surgical manipulation of an open eye alone alters the micro-environmental balance of a portion of the eye, thereby affecting the pupil. environmental balance and thus affect the pupil. These issues need to be further investigated and explored.

Our study had some limitations. The postoperative observation time was only 1 month, which is relatively short. We will continue to monitor the long-term postoperative pupillary changes. Moreover, the small sample size makes it impossible to accurately analyze the data and draw more definite conclusions. We will continue to expand the sample size and perform relevant studies.

#### 4.1. Value Statement

##### 4.1.1. What was Known

1. Previous studies have found that ICL implantation can significantly reduce pupil size in the short term after surgery.

2. There are few studies on dynamic changes in pupils during ICL surgery.

##### 4.1.2. What this Paper Adds

1. This is the first study to compare the changes in pupil diameter and dynamic changes in different diopter groups.

2. This study is the first to study pupil changes in ICL surgery without viscoelastic agent implantation.

3. In this study, it was found for the first time that the pupils of different diopter groups showed different changes after ICL implantation.

#### CONCLUSION

This study attempts to compare the influence of ICL implantation on the pupil of people with different diopters and to study the relationship between the pupil change response and diopter, so as to provide a certain research basis for the influence of visual quality brought by the pupil.

#### LIST OF ABBREVIATIONS

ICL = Implantable Collamer Lens

IOP = Intraocular Pressure

#### ETHICS APPROVAL AND CONSENT TO PARTICIPATE

The study was approved by the ethics committee of Beijing Anzhen hospital.

#### HUMAN AND ANIMAL RIGHTS

No animals were used in this research. All procedures



performed in studies involving human participants were in accordance with the ethical standards of institutional and/or research committee and with the 1975 declaration of Helsinki, as revised in 2013.

#### CONSENT FOR PUBLICATION

Written informed consent was obtained from all participants.

#### STANDARDS OF REPORTING

STROBE guidelines were followed.

#### AVAILABILITY OF DATA AND MATERIALS

The data and supportive information is available within the article.

#### FUNDING

None.

#### CONFLICT OF INTEREST

The authors declare no conflict of interest financial or otherwise.

#### ACKNOWLEDGEMENTS

Declared none.

#### REFERENCES

- [1] Kawamori T, Shimizu K, Shoji N. Theoretical study on the need for laser iridotomy in an implantable collamer lens with a hole using computational fluid dynamics. *Eye* 2017; 31(5): 795-801. [http://dx.doi.org/10.1038/eye.2016.279] [PMID: 28106892]
- [2] Garcia-De la Rosa G, Olivo-Payne A, Serna-Ojeda JC, *et al.* Anterior segment optical coherence tomography angle and vault analysis after toric and non-toric implantable collamer lens V4c implantation in patients with high myopia. *Br J Ophthalmol* 2018; 102(4): 544-8. [http://dx.doi.org/10.1136/bjophthalmol-2017-310518] [PMID: 28729370]
- [3] Chun YS, Park IK, Lee HI, Lee JH, Kim JC. Iris and trabecular meshwork pigment changes after posterior chamber phakic intraocular lens implantation. *J Cataract Refract Surg* 2006; 32(9): 1452-8. [http://dx.doi.org/10.1016/j.jcrs.2006.04.023] [PMID: 16931255]
- [4] Mastropasqua L, Carpineto P, Ciancaglini M, Falconio G. Intraocular pressure changes after phacoemulsification and foldable silicone lens implantation using Healon GV. *Ophthalmologica* 1998; 212(5): 318-21. [http://dx.doi.org/10.1159/000027315] [PMID: 9693288]
- [5] Pan AP, Wen LJ, Shao X, *et al.* A novel ophthalmic viscosurgical device-free phakic intraocular lens implantation makes myopic surgery safer. *Eye Vis* 2020; 7(1): 18. [http://dx.doi.org/10.1186/s40662-020-00185-4] [PMID: 32280722]
- [6] Li D, Yang Y, Su C, Yin H, Liu X. Pupil diameter changes in high myopes after collamer lens implantation. *Optom Vis Sci* 2015; 92(12): 1161-9. [http://dx.doi.org/10.1097/OPX.0000000000000723] [PMID: 26501842]
- [7] Keuch RJ, Bleckmann H. Pupil diameter changes and reaction after posterior chamber phakic intraocular lens implantation. *J Cataract Refract Surg* 2002; 28(12): 2170-2. [http://dx.doi.org/10.1016/S0886-3350(02)01355-X] [PMID: 12498854]
- [8] Miao H, Chen X, Tian M, Chen Y, Wang X, Zhou X. Refractive outcomes and optical quality after implantation of posterior chamber phakic implantable collamer lens with a central hole (ICL V4c). *BMC Ophthalmol* 2018; 18(1): 141. [http://dx.doi.org/10.1186/s12886-018-0805-3] [PMID: 29898694]
- [9] Miao HM, Niu L-L, Zhao J, Wang X-Y, Zhou X-T, Zhou XT. One-step viscoelastic agent technique for ICL V4c implantation for myopia. *Int J Ophthalmol* 2021; 14(9): 1359-64. [http://dx.doi.org/10.18240/ijo.2021.09.10] [PMID: 34540611]
- [10] Senthil S, Choudhari NS, Vaddavalli PK, Murthy S, Reddy J, Garudadi CS. Etiology and management of raised intraocular pressure following posterior chamber phakic intraocular lens implantation in myopic eyes. *PLoS One* 2016; 11(11): e0165469. [http://dx.doi.org/10.1371/journal.pone.0165469] [PMID: 27855172]
- [11] Niruthisard D, Kasetsuwan N. Unilateral iritis-zavalta syndrome after implantable collamer lens implantation: A case report and review of the literature. *J Med Case Reports* 2021; 15(1): 467. [http://dx.doi.org/10.1186/s13256-021-03063-2] [PMID: 34548112]
- [12] Lim DH, Lyu JJ, Choi SH, Chung ES, Chung TY. Risk factors associated with night vision disturbances after phakic intraocular lens implantation. *Am J Ophthalmol* 2014; 157(1): 135-141.e1. [http://dx.doi.org/10.1016/j.ajo.2013.09.004] [PMID: 24182745]
- [13] Gonzalez-Lopez F, Bouza-Miguens C, Tejerina V, *et al.* Dynamic assessment of variations in pupil diameter using swept-source anterior segment optical coherence tomography after phakic collamer lens implantation. *Eye Vis* 2021; 8(1): 39. [http://dx.doi.org/10.1186/s40662-021-00262-2] [PMID: 34688308]
- [14] Zhu Y, Yue Y, Zhu H, Chen J, Zhou J. Influence of refractive error on pupil diameters in highly myopic eyes with implantable collamer lenses. *Eur J Ophthalmol* 2020; 30(6): 1328-34. [http://dx.doi.org/10.1177/1120672119863716] [PMID: 31304777]
- [15] Totsuka K, Ishikawa H, Kamiya K, Shoji N, Shimizu K. Pupil dynamics induced by light reflex after posterior chamber phakic intraocular lens implantation. *J Refract Surg* 2017; 33(10): 704-7. [http://dx.doi.org/10.3928/1081597X-20170721-06] [PMID: 28991339]
- [16] Kato S, Shimizu K, Igarashi A. Vault changes caused by light-induced pupil constriction and accommodation in eyes with an implantable collamer lens. *Cornea* 2019; 38(2): 217-20. [http://dx.doi.org/10.1097/ICO.0000000000001785] [PMID: 30371566]

