



# Noninvasive Detection of Retinal Vascular Changes in Eyes with Non-arteritic Anterior Ischemic Optic Neuropathy

Shuo Sun<sup>1,#</sup>, Qianhui Yang<sup>1,#</sup>, Ting Liu<sup>1,#</sup>, Kaiwen Hei<sup>1</sup>, Yifeng Ke<sup>1</sup>, Wei Wang<sup>2</sup>, Quanhong Han<sup>3</sup>, Xiaorong Li<sup>1,\*</sup> and Longli Zhang<sup>1,\*</sup>

<sup>1</sup>Tianjin Key Laboratory of Retinal Functions and Diseases, Tianjin Branch of National Clinical Research Center for Ocular Disease, Eye Institute and School of Optometry, Tianjin Medical University Eye Hospital, Tianjin 300384, China

<sup>2</sup>Vitreous and Retina Department, Hebei Eye Hospital, Xingtai 054000, Hebei Province, China

<sup>3</sup>Tianjin Eye Hospital, Tianjin Key Lab of Ophthalmology and Visual Science, Tianjin Eye Institute, Clinical College of Ophthalmology Tianjin Medical University, Tianjin 300020, China

## Abstract:

**Objective:** This study aimed to evaluate retinal vessel morphology in Non-arteritic Anterior Ischemic Optic Neuropathy (NAION) using Integrative Vessel Analysis (IVAN) and to explore the relationships between retinal vascular parameters and systemic factors related to NAION.

**Methods:** This case-control study included 120 eyes from 120 participants, categorized into control, hypertension, and NAION groups (40 eyes each). IVAN was used to measure retinal vessel caliber through the central retinal artery equivalent (CRAE) and central retinal vein equivalent (CRVE).

**Results:** The mean CRAE and CRVE across all participants were  $154.54 \pm 21.53 \mu\text{m}$  and  $252.22 \pm 15.88 \mu\text{m}$ , respectively. NAION participants exhibited higher CRAE and CRVE compared to the control and hypertension groups. In the NAION group, body mass index (BMI) showed a negative correlation with CRAE and a positive correlation with CRVE.

**Conclusion:** IVAN serves as a reliable method for assessing retinal vascular caliber. Our findings suggest that retinal vascular caliber may provide valuable insights into the role of subclinical retinal vascular processes in the development of NAION.

**Keywords:** Non-arteritic anterior ischemic optic neuropathy, Integrative vessel analysis, Retinal vascular caliber, Central retinal artery equivalent, Central retinal vein equivalent, Arteriole to venule ratio.

© 2024 The Author(s). Published by Bentham Open.

This is an open access article distributed under the terms of the Creative Commons Attribution 4.0 International Public License (CC-BY 4.0), a copy of which is available at: <https://creativecommons.org/licenses/by/4.0/legalcode>. This license permits unrestricted use, distribution, and reproduction in any medium, provided the original author and source are credited.

\*Address correspondence to these authors at the Tianjin Key Laboratory of Retinal Functions and Diseases, Tianjin Branch of National Clinical Research Center for Ocular Disease, Eye Institute and School of Optometry, Tianjin Medical University Eye Hospital, Tianjin 300384, China; E-mails: zhanglonglieye@126.com and xiaorli@163.com

#These authors contributed equally to this work

Cite as: Sun S, Yang Q, Liu T, Hei K, Ke Y, Wang W, Han Q, Li X, Zhang L. Noninvasive Detection of Retinal Vascular Changes in Eyes with Non-arteritic Anterior Ischemic Optic Neuropathy. *Open Ophthalmol J*, 2024; 18: e18743641344967. <http://dx.doi.org/10.2174/0118743641344967241105095401>



Received: July 18, 2024  
Revised: October 20, 2024  
Accepted: October 29, 2024  
Published: November 15, 2024



Send Orders for Reprints to  
[reprints@benthamscience.net](mailto:reprints@benthamscience.net)

## 1. INTRODUCTION

Non-arteritic Anterior Ischemic Optic Neuropathy (NAION) is one of the most prevalent conditions affecting individuals over 50 years of age, leading to irreversible

vision loss [1]. However, its pathogenesis, clinical features, and treatment options still remain controversial [2]. Several local risk factors for NAION have been identified, including insufficient blood supply to the optic nerve head and compromised watershed microcirculation

[3, 4]. Numerous researchers [1, 5, 6] have suggested that “disc at risk” plays a role in the pathogenesis of NAION. Additionally, various systemic risk factors, such as metabolic syndrome (MetS), gender, and age, may also act as triggers [7-9].

The retinal vasculature offers a unique window to non-invasively and directly assess vascular segments *in vivo*, reflecting circulatory efficiency. Advancements in digital retinal photography and software have significantly enhanced our ability to measure the characteristics of retinal vessels with greater convenience [10, 11]. Integrative Vessel Analysis (IVAN), a novel software designed by the University of Wisconsin, allows for the measurement of retinal vessel caliber using fundus images [12]. Given that NAION is considered to stem from vascular insufficiency [13, 14], we hypothesized that vascular diameter is a risk factor for NAION. In this study, we used IVAN to measure retinal vessel caliber from fundus photographs to assess its relevance to the progression of NAION. Additionally, the correlation between retinal vascular parameters and NAION-related systemic factors was assessed.

## 2. MATERIALS AND METHODS

### 2.1. Participants

The study was conducted at Tianjin Medical University Eye Hospital between July, 2015 to July, 2019. It was performed in line with the principles of the Declaration of Helsinki. Approval was granted by the Ethics Committee of Tianjin Medical University Eye Hospital. Prior to the initiation of the study, all participants were informed about the research procedures and were required to provide written consent.

One hundred twenty participants were recruited from Tianjin Medical University Eye Hospital and divided into three groups: normal group (normal), hypertension group (hyper), and NAION group (NAION). The criteria are as follows: a) The normal group included patients without any systemic or ocular diseases, with Best Corrected Visual Acuity (BCVA) >20/63 and intraocular pressure (IOP) <21 mmHg. Participants with significant turbidity of the refractive medium were excluded. b) Hyper group consisted of 40 participants with a diagnosis of hypertension (Systolic BP (SBP) < 120 mmHg and Diastolic BP (DBP) < 80 mmHg), who did not have any other systemic diseases, such as coronary heart disease, stroke, or diabetes mellitus. The criteria for the NAION group included: 1) a history of sudden visual loss and/or optic disc-related visual field defects; 2) a swollen optic disc with or without linear hemorrhages; 3) the presence of a relative afferent pupillary defect (RAPD). Exclusion criteria for the NAION group included any ocular diseases or factors that could affect BCVA and/or visual field, such as giant cell arteritis and any prior treatment for NAION.

### 2.2. Data Collection and Imaging Analysis

The subjects underwent a thorough ophthalmic evaluation, including BCVA, IOP with a noncontact

pneumatic tonometer (Canon T-2; Canon, Tokyo), slit-lamp biomicroscopy, and fundus examination. Other examinations, including swept-source optical coherence tomography (SS-OCT), fluorescein angiography, and indocyanine green angiography (FA/ICGA), were performed. Medical history, such as age, gender, and body mass index (BMI), was also recorded to evaluate their relevance with retinal vascular parameters.

For all participants, 30-degree fundus color photographs of the eye centered on the disc were taken. Retinal vascular calibers were measured by IVAN (University of Wisconsin, Madison), a computer program that was based on a detailed protocol [15]. Briefly, the IVAN protocol required that vessel diameters should be away from the six largest arterioles and six largest venules located in a zone of 0.5 to 1.0 disc diameters from the disc margin. The measurement was performed by two ophthalmologists, who were masked to the characteristics of the patients.

### 2.3. Statistical Analysis

All the statistical analyses in this study were conducted using SPSS statistics version 25.0 (SPSS Inc., Chicago, IL). Variables were presented as mean  $\pm$  standard deviations. A one-way analysis of variance (ANOVA) was used for multiple mean comparisons, and then the Tukey HSD test was performed to assess the significance of the differences between each group.

For univariate analysis, Spearman's rank correlation coefficient test was performed to evaluate the significance of the correlations between the retinal vascular calibers and NAION systematic factors. A p-value of <0.05 was considered statistically significant.

## 3. RESULTS

### 3.1. Quantification and Analysis of CRAE and CRVE among Groups

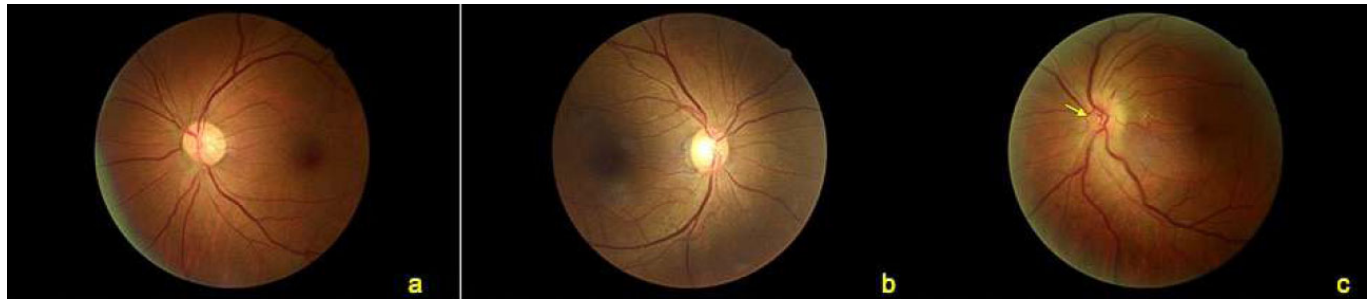
The baseline characteristics of the patients are summarized in Table 1. A total of 120 patients (81 women and 39 men) participated in our study, which divided them into three groups: the normal group (Normal), the hypertension group (Hyper), and the NAION group (NAION). Fig. (1) presents representative images for each group. No significant differences in age or gender were observed among the three groups at baseline.

We assessed the Central Retinal Artery Equivalent (CRAE) and Central Retinal Vein Equivalent (CRVE) in each group using the IVAN software, with representative images shown in Fig. (2). The overall measurements for CRAE and CRVE across all patients were  $154.54 \pm 21.53 \mu\text{m}$  and  $252.22 \pm 15.88 \mu\text{m}$ , respectively. In the normal group, CRAE and CRVE were  $154.05 \pm 11.72 \mu\text{m}$  and  $237.60 \pm 13.98 \mu\text{m}$ , respectively. The hyper group showed CRAE and CRVE values of  $150.05 \pm 15.12 \mu\text{m}$  and  $242.26 \pm 14.53 \mu\text{m}$ , respectively. In contrast, the NAION group exhibited CRAE and CRVE values of  $159.6 \pm 17.07 \mu\text{m}$  and  $277.17 \pm 26.58 \mu\text{m}$ , respectively.

**Table 1. Baseline characteristics of involved patients.**

Characteristics	Total Participants (n=120)	Normal Participants (n=40)	Hypertension Participants (n=40)	NAION Participants (n=40)	p value
Age, year	58 ±9.98	53 ±10.04	56 ±8.01	58 ±11.4	0.0803
Gender, female%	81, 67.5%	29, 72.5%	26, 65%	26, 65%	0.7104
CRAE, μm	154.54 ±21.53	154.05 ±11.72	150.05 ±15.12	159.60 ±17.07	0.0173
CRVE, μm	252.22 ±15.88	237.60 ±13.98	242.26 ± 14.53	277.17 ±26.58	<0.0001

**Abbreviations:** CRAE: central retinal artery equivalent.  
 CRVE: central retinal vein equivalent.



**Fig. (1).** Fundus images illustrating characteristics of each group: **a.** Fundus image of a normal patient, **b.** Fundus image of a patient with hypertension, and **c.** Fundus image of a patient with NAION. The yellow arrow indicates a small optic disc and an absent cup (disc at risk).

Notably, a significant difference in CRAE was found among the three groups ( $p=0.017$ ). Post hoc analyses indicated that the CRAE was significantly larger in the

NAION group compared to the hyper group ( $p=0.013$ ). However, no significant difference was found between the hyper and normal groups ( $p=0.451$ ) (Fig. 3A).

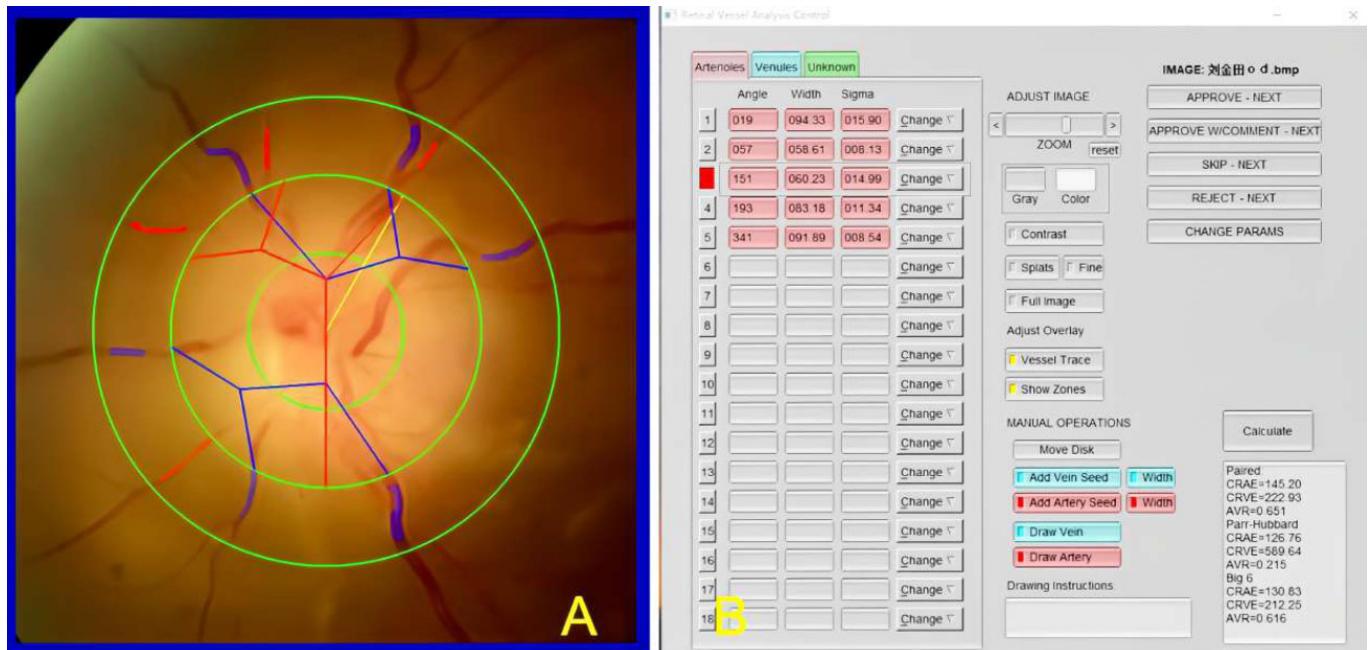
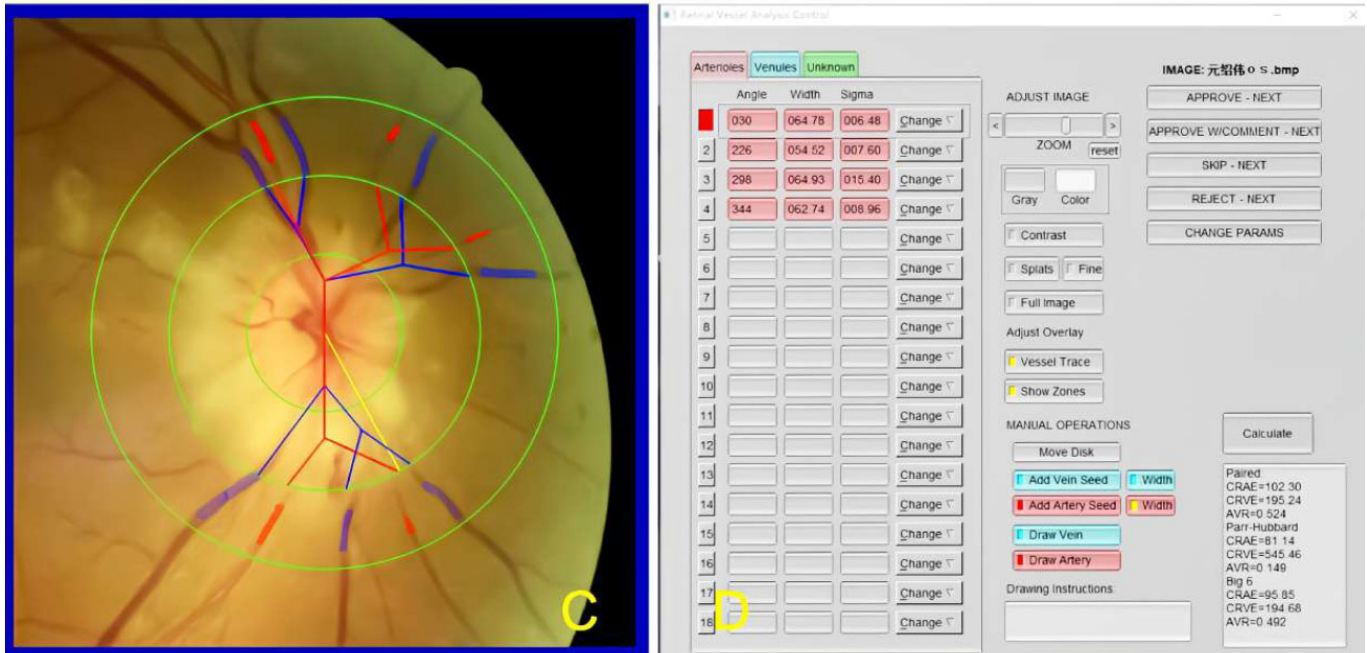
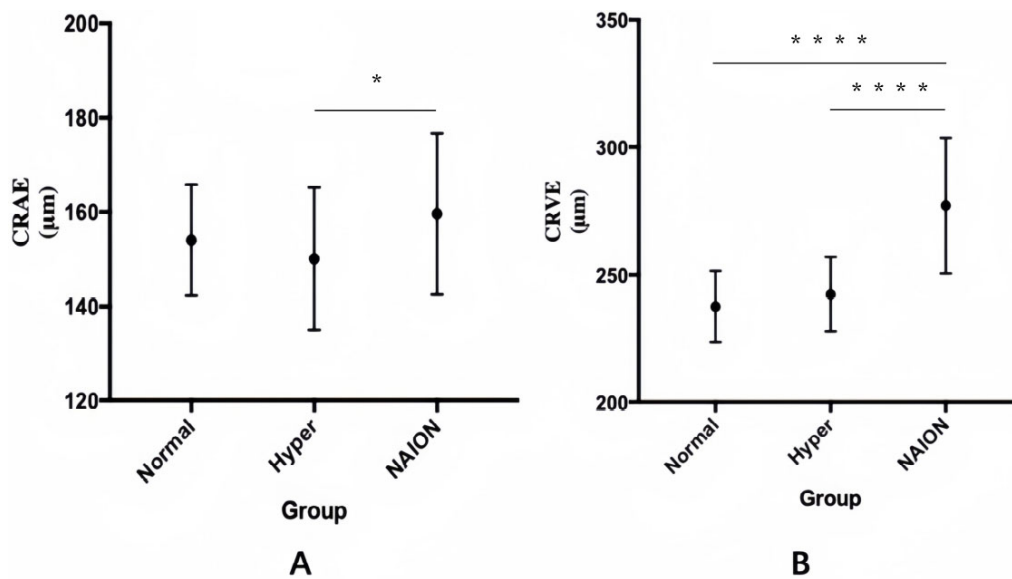


Fig. 2 contd.....



**Fig. (2).** Representative IVAN measurement of vascular caliber. Arterioles are in red, and venules are in blue. The retinal vascular caliber was measured and standardized within the region spanning from 0.5 to 2.0 disc diameters away from the disc margin. **A, C:** Measurement of vascular caliber. **B, D:** Calibers measured using IVAN software.



**Fig. (3).** Distribution of retinal microvascular diameters. **A.** CRAE comparison; **B.** CRVE comparison. Data presented are mean ± standard deviation (SD) \*: statistically different,  $p < 0.05$ .

Furthermore, a significant difference in CRVE was observed among the three groups ( $p < 0.0001$ ). Post hoc comparisons revealed that CRVE was significantly larger in the NAION group compared to the hyper group ( $p < 0.0001$ ) and the normal group ( $p < 0.0001$ ). The NAION

group consistently exhibited larger CRVE values than the other groups, while no significant difference was found between the hyper and normal groups ( $p = 0.527$ ) (Fig. 3B).

**Table 2. Association of retinal vessel caliber with systemic factors.**

Systemic Factors	Normal ( <i>r</i> , <i>p</i> value)	Hypertension ( <i>r</i> , <i>p</i> value)	NAION ( <i>r</i> , <i>p</i> value)
<i>CRAE</i>	-	-	-
Age, year	-0.140 (0.396)	-0.082 (0.616)	0.110 (0.499)
Gender	0.001 (0.994)	0.222 (0.188)	0.047 (0.770)
BMI	-0.10 (0.32)	0.03 (0.79)	-0.04 (0.04)
<i>CRVE</i>	-	-	-
Age, year	-0.110 (0.504)	-0.122 (0.454)	-0.196 (0.225)
Gender	-0.156 (0.343)	-0.215 (0.184)	-0.08 (0.622)
BMI	0.104 (0.29)	0.016 (0.95)	0.01 (0.95)

**Abbreviations:** CRAE: central retinal artery equivalent.

CRVE: central retinal vein equivalent.

### 3.2. Correlation between Retinal Vessel Caliber and Systemic Factors

The associations between age, gender, and both CRAE and CRVE in each group are presented in Table 2. In the normal ( $r = -0.140$ ,  $p = 0.396$ ) and hypertension groups ( $r = -0.082$ ,  $p = 0.616$ ), CRAE appeared to correlate inversely with age, while a positive correlation was observed in the NAION group ( $r = 0.110$ ,  $p = 0.499$ ). Additionally, CRAE was positively associated with male gender across all groups (Normal:  $r = 0.001$ ,  $p = 0.994$ ; Hypertension:  $r = 0.222$ ,  $p = 0.118$ ; NAION:  $r = 0.047$ ,  $p = 0.770$ ). For CRVE, an inverse correlation with age was noted across all three groups (Normal:  $r = -0.110$ ,  $p = 0.504$ ; Hypertension:  $r = -0.122$ ,  $p = 0.454$ ; NAION:  $r = -0.196$ ,  $p = 0.225$ ), while CRVE showed a correlation with female gender (Normal:  $r = -0.156$ ,  $p = 0.343$ ; Hypertension:  $r = -0.215$ ,  $p = 0.184$ ; NAION:  $r = -0.08$ ,  $p = 0.622$ ). A recent study identified BMI as an independent risk factor for NAION, suggesting that controlling BMI could slow disease progression [16]. In our study, we found that BMI was negatively correlated with CRAE ( $r = -0.10$ ,  $p = 0.04$ ) and positively correlated with CRVE ( $r = 0.016$ ,  $p = 0.01$ ).

## 4. DISCUSSION

NAION is a multifactorial ocular disease. The primary mechanism underlying NAION is believed to be acute hypoperfusion of the optic nerve due to compromised posterior ciliary artery branches. Specifically, transient or permanent reduction in blood flow through the short posterior ciliary arteries, which supply the optic nerve head (ONH), may trigger optic disc edema. This can lead to compartment syndrome in the non-expandable area between the ONH surface and the lamina cribrosa, particularly in structurally predisposed, crowded optic discs. Secondary inflammation may further exacerbate damage to optic nerve axons and glial tissue, ultimately leading to retinal ganglion cell death through apoptosis [17, 18]. Since the exact pathophysiology of NAION remains unclear, examining retinal vascular morphology may provide valuable insights into the disease's pathological processes from a fresh perspective.

Currently, several methods are used to measure retinal vascular caliber from fundus images [19-21]. The IVAN

method provides a noninvasive approach to assess retinal vessel changes, often serving as a marker for systemic factors, such as age and hypertension [22]. In this study, the retinal vessel calibers in the NAION group were significantly larger than those in the other groups, suggesting that the vessels in NAION patients were markedly dilated, which may be linked to the ischemic state observed in these patients [23]. The two most widely accepted explanations for NAION include the presence of a small, crowded optic disc and associated systemic comorbidities [24]. Previous studies have reported that NAION patients have a higher prevalence of small or absent optic cups, which may lead to optic nerve fiber crowding and limited space within the optic disc [25, 26]. Ischemia triggers vessel dilation as a compensatory response, allowing tissues to receive adequate oxygen.

In comparing CRAE, we found a significant increase in the NAION group compared to the normal group. We hypothesize that this arterial enlargement is due to the hypoxic conditions in the retinal environment in NAION. Under hypoxic stress, vasodilation occurs to improve blood perfusion to affected tissues [27], driven by the activation of KATP channels and a reduction in ATP in vascular smooth muscle cells, resulting in dilation [28]. Additionally, CRVE measurements revealed that the NAION group exhibited the largest retinal venous dimensions, which is consistent with previous findings on NAION. This abnormality may hinder central retinal venous return, elevate retinal venous pressure, and contribute to venous dilation [29]. In normal clinical assessments, the arteriolar-to-venular ratio (AVR) is typically around 2:3. Our findings showed that the AVR in the NAION group was the lowest among the three groups, indicating that venous dilation was more pronounced in NAION patients compared to the other groups. This result aligns with previous studies [30].

Age, gender, and BMI have been extensively discussed as risk factors for NAION in numerous studies. It has been well established that older individuals tend to have narrower vascular calibers across various studies and populations [31-33], an inverse correlation that aligns with our findings. Previous research demonstrated that a higher BMI was associated with narrower retinal arteriolar caliber in six-year-old children [34], while a recent meta-analysis also showed that smaller retinal arteriolar caliber

correlated with increasing age and higher BMI [35]. These results are consistent with those of our study, where we observed that CRAE was narrower in patients with higher BMI while CRVE was wider. However, Xiao *et al.* reported no significant correlation between retinal caliber and BMI [36].

Diabetes mellitus (DM) is widely recognized as a major risk factor for vascular diseases, significantly influencing retinal vessel calibers [37]. Li *et al.* found that mothers with gestational diabetes mellitus (GDM) exhibited narrower retinal vessels, reduced fractal dimensions, and larger branching angles, suggesting that hyperglycemia may contribute to small-vessel abnormalities [38]. The vasoconstrictive effect observed in DM patients is likely due to the hyperglycemic state [39]. However, we did not include DM status in our study for several reasons. First, DM can affect vessel caliber measurements, and we aimed to focus on NAION without introducing additional confounding factors. Second, incorporating three conditions (NAION, hypertension, and DM) might complicate the analysis by affecting NAION incidence. Several studies have identified a strong association between hypertension and the development of NAION, particularly in individuals under 50 years of age. Therefore, we included patients with hypertension in this study to facilitate direct comparisons between the hypertension and normal groups, as well as between the NAION and normal groups.

Our findings may have significant clinical implications for NAION. First, this study provides insights into the assessment of vascular caliber in NAION patients, suggesting that CRAE and CRVE measurements could serve as valuable markers for the disease. Second, these data could offer therapeutic value in managing NAION patients. However, our study has some limitations. It was limited to Chinese patients, so including other ethnic groups would be essential to improve the generalizability of the findings. Additionally, our sample size of 120 patients was relatively small, and future studies should aim to include larger cohorts.

## CONCLUSION

Our result suggested the assessment of the CRAE and CRVE may serve as valuable markers for identifying NAION patients, highlighting the importance of paying closer attention to subclinical vascular abnormalities. Additionally, IVAN is recommended as a reliable method for measuring vascular caliber in patients with NAION and for monitoring the occurrence of NAION in the contralateral eye.

## AUTHORS' CONTRIBUTION

X. L. and L. Z.: Study conception and design; T. L., K. H., and Q. H.: Data collection; Y. K. and W. W.: Analysis and interpretation of results; K. H., Q. Y., and S. S.: Draft manuscript.

## ETHICS APPROVAL AND CONSENT TO PARTICIPATE

Ethics approval was granted by the ethics committee of Tianjin Medical University Eye Hospital (2022KY-18).

## HUMAN AND ANIMAL RIGHTS

All human research procedures followed were in accordance with the ethical standards of the committee responsible for human experimentation (institutional and national), and with the Helsinki Declaration of 1975, as revised in 2013.

## CONSENT FOR PUBLICATION

Prior to the initiation of the study, all participants were informed and asked to provide written consent.

## STANDARDS OF REPORTING

STROBE guidelines were followed.

## AVAILABILITY OF DATA AND MATERIAL

All data generated or analyzed during this study are included in this published article.

## FUNDING

This study was supported by the Independent and Open Project of Tianjin Key Laboratory of Retinal Function and Diseases (2020tjswmm004), Tianjin Health Research Project (TJWJ2024QN026), and Tianjin Key Medical Discipline (Specialty) Construction Project (TJYXZDXK-037A).

## CONFLICT OF INTEREST

The authors declare no conflict of interest, financial or otherwise.

## ACKNOWLEDGEMENTS

Declared none.

## REFERENCES

- [1] Bioussé V, Newman NJ. Ischemic Optic Neuropathies. *N Engl J Med* 2015; 373(17): 1677. PMID: 26488706
- [2] Hayreh SS. Ischemic optic neuropathies - where are we now? *Graefes Arch Clin Exp Ophthalmol* 2013; 251(8): 1873-84. <http://dx.doi.org/10.1007/s00417-013-2399-z> PMID: 23821118
- [3] Hayreh SS. Blood flow in the optic nerve head and factors that may influence it. *Prog Retin Eye Res* 2001; 20(5): 595-624. [http://dx.doi.org/10.1016/S1350-9462\(01\)00005-2](http://dx.doi.org/10.1016/S1350-9462(01)00005-2) PMID: 11470452
- [4] Wilhelm H, Beisse F, Rütger K. Die nicht arteriitische anteriore ischämische Optikusneuropathie (NAION). *Klin Monatsbl Augenheilkd* 2015; 232(11): 1260-9. <http://dx.doi.org/10.1055/s-0035-1558170> PMID: 26575534
- [5] Pomeranz HD, Smith KH, Hart WM Jr, Egan RA. Sildenafil-associated nonarteritic anterior ischemic optic neuropathy. *Ophthalmology* 2002; 109(3): 584-7. [http://dx.doi.org/10.1016/S0161-6420\(01\)00976-9](http://dx.doi.org/10.1016/S0161-6420(01)00976-9) PMID: 11874765
- [6] Burde RM. Optic disk risk factors for nonarteritic anterior ischemic optic neuropathy. *Am J Ophthalmol* 1993; 116(6): 759-64. [http://dx.doi.org/10.1016/S0002-9394\(14\)73478-6](http://dx.doi.org/10.1016/S0002-9394(14)73478-6) PMID: 8250081
- [7] Hayreh SS, Joos KM, Podhajsky PA, Long CR. Systemic diseases associated with nonarteritic anterior ischemic optic neuropathy. *Am J Ophthalmol* 1994; 118(6): 766-80. [http://dx.doi.org/10.1016/S0002-9394\(14\)72557-7](http://dx.doi.org/10.1016/S0002-9394(14)72557-7) PMID: 7977604
- [8] Hayreh SS, Podhajsky P, Zimmerman MB. Role of nocturnal arterial hypotension in optic nerve head ischemic disorders.

- Ophthalmologica. Journal international d'ophtalmologie. International journal of ophthalmology. Z Augenheilkd 1999; 213(2): 76-96.
- [9] Archer EL, Pepin S. Obstructive sleep apnea and nonarteritic anterior ischemic optic neuropathy: evidence for an association. *J Clin Med* 2013; 9(6): 613-8. <http://dx.doi.org/10.5664/jcsm.2766>
- [10] Hussain N, Edraki M, Tahhan R, *et al.* Telemedicine for diabetic retinopathy screening using an ultra-widefield fundus camera. *Clin Ophthalmol* 2017; 11: 1477-82. <http://dx.doi.org/10.2147/OPHT.S135287> PMID: 28860696
- [11] Li L, Zhang P, Liu H, Liu YH, Gao L. EVALUATION OF MULTISPECTRAL IMAGING IN DIAGNOSING DIABETIC RETINOPATHY. *Retina* 2019; 39(9): 1701-9. <http://dx.doi.org/10.1097/IAE.0000000000002225> PMID: 29901495
- [12] Wong TY, Islam FMA, Klein R, *et al.* Retinal vascular caliber, cardiovascular risk factors, and inflammation: the multi-ethnic study of atherosclerosis (MESA). *Invest Ophthalmol Vis Sci* 2006; 47(6): 2341-50. <http://dx.doi.org/10.1167/iovs.05-1539> PMID: 16723443
- [13] Callizo J, Feltgen N, Ammermann A, *et al.* Atrial fibrillation in retinal vascular occlusion disease and non-arteritic anterior ischemic optic neuropathy. *PLoS One* 2017; 12(8): e0181766. <http://dx.doi.org/10.1371/journal.pone.0181766> PMID: 28771491
- [14] Rootman J, Butler D. Ischaemic optic neuropathy--a combined mechanism. *Br J Ophthalmol* 1980; 64(11): 826-31. <http://dx.doi.org/10.1136/bjo.64.11.826> PMID: 7426554
- [15] Hubbard LD, Brothers RJ, King WN, *et al.* Methods for evaluation of retinal microvascular abnormalities associated with hypertension/sclerosis in the Atherosclerosis Risk in Communities Study. *Ophthalmology* 1999; 106(12): 2269-80. [http://dx.doi.org/10.1016/S0161-6420\(99\)90525-0](http://dx.doi.org/10.1016/S0161-6420(99)90525-0) PMID: 10599656
- [16] Xiao YY, Wei WB, Wang YX, *et al.* Systemic-related factors of nonarteritic anterior ischemic optic neuropathy. *Chin Med J* 2018; 131(19): 2357-9. <http://dx.doi.org/10.4103/0366-6999.241795> PMID: 30246725
- [17] Lee EJ, Han JC, Park DY, Kee C. A neuroglia-based interpretation of glaucomatous neuroretinal rim thinning in the optic nerve head. *Prog Retin Eye Res* 2020; 77: 100840. <http://dx.doi.org/10.1016/j.preteyeres.2020.100840> PMID: 31982595
- [18] Bruera MG, Benedetto MM, Guido ME, Degano AL, Contin MA. Glial cell response to constant low light exposure in rat retina. *Vis Neurosci* 2022; 39: E005. <http://dx.doi.org/10.1017/S0952523822000049> PMID: 36164752
- [19] Rassam SM, Patel V, Brinchmann-Hansen O, Engvold O, Kohner EM. Accurate vessel width measurement from fundus photographs: a new concept. *Br J Ophthalmol* 1994; 78(1): 24-9. <http://dx.doi.org/10.1136/bjo.78.1.24> PMID: 8110693
- [20] Suzuki Y. Direct measurement of retinal vessel diameter: comparison with microdensitometric methods based on fundus photographs. *Surv Ophthalmol* 1995; 39 (Suppl. 1): S57-65. [http://dx.doi.org/10.1016/S0039-6257\(05\)80074-8](http://dx.doi.org/10.1016/S0039-6257(05)80074-8) PMID: 7660313
- [21] Wu DC, Schwartz B, Schwoerer J, Banwatt R. Retinal blood vessel width measured on color fundus photographs by image analysis. *Acta Ophthalmol Scand Suppl* 1995; 73(215): 33-40. <http://dx.doi.org/10.1111/j.1600-0420.1995.tb00590.x> PMID: 8846248
- [22] Ikram MK, Ong YT, Cheung CY, Wong TY. Retinal vascular caliber measurements: clinical significance, current knowledge and future perspectives. *Ophthalmologica* 2013; 229(3): 125-36. <http://dx.doi.org/10.1159/000342158> PMID: 23006932
- [23] Distefano AG, Lam BL. Non-arteritic anterior ischemic optic neuropathy in pilots. *Aerosp Med Hum Perform* 2018; 89(11): 1005-7. <http://dx.doi.org/10.3357/AMHP.5177.2018> PMID: 30352654
- [24] Hayreh SS. Management of ischemic optic neuropathies. *Indian J Ophthalmol* 2011; 59(2): 123-36. <http://dx.doi.org/10.4103/0301-4738.77024> PMID: 21350282
- [25] Beck RW, Servais GE, Hayreh SS. Anterior ischemic optic neuropathy. IX. Cup-to-disc ratio and its role in pathogenesis. *Ophthalmology* 1987; 94(11): 1503-8. [http://dx.doi.org/10.1016/S0161-6420\(87\)33263-4](http://dx.doi.org/10.1016/S0161-6420(87)33263-4) PMID: 3684223
- [26] Hayreh SS, Zimmerman MB. Non-arteritic anterior ischemic optic neuropathy: role of systemic corticosteroid therapy. *Graefes Arch Clin Exp Ophthalmol* 2008; 46(7): 1029-46. <http://dx.doi.org/10.1007/s00417-008-0805-8> PMID: 18404273
- [27] Dart C, Standen NB. Activation of ATP-dependent K<sup>+</sup> channels by hypoxia in smooth muscle cells isolated from the pig coronary artery. *J Physiol* 1995; 483(Pt 1): 29-39.
- [28] Peers C, Kemp PJ. Acute oxygen sensing: diverse but convergent mechanisms in airway and arterial chemoreceptors. *Respir Res* 2001; 2(3): 145-9. <http://dx.doi.org/10.1186/rr51> PMID: 11686878
- [29] Bernstein SL, Johnson MA, Miller NR. Nonarteritic anterior ischemic optic neuropathy (NAION) and its experimental models. *Prog Retin Eye Res* 2011; 30(3): 167-87. <http://dx.doi.org/10.1016/j.preteyeres.2011.02.003> PMID: 21376134
- [30] Cooper LS, Wong TY, Klein R, *et al.* Retinal microvascular abnormalities and MRI-defined subclinical cerebral infarction: the Atherosclerosis Risk in Communities Study. *Stroke* 2006; 37(1): 82-6. <http://dx.doi.org/10.1161/01.STR.0000195134.04355.e5> PMID: 16306463
- [31] Wong TY, Klein R, Klein BEK, Meuer SM, Hubbard LD. Retinal vessel diameters and their associations with age and blood pressure. *Invest Ophthalmol Vis Sci* 2003; 44(11): 4644-50. <http://dx.doi.org/10.1167/iovs.03-0079> PMID: 14578380
- [32] Kawasaki R, Wang JJ, Rochtchina E, *et al.* Cardiovascular risk factors and retinal microvascular signs in an adult Japanese population: the Funagata Study. *Ophthalmology* 2006; 113(8): 1378-84. <http://dx.doi.org/10.1016/j.ophtha.2006.02.052> PMID: 16877076
- [33] Klein R, Klein BE, Moss SE, Wong TY, Sharrett AR. Retinal vascular caliber in persons with type 2 diabetes: the Wisconsin Epidemiological Study of Diabetic Retinopathy: XX. *Ophthalmology* 2006; 113(9): 1488-98. <http://dx.doi.org/10.1016/j.ophtha.2006.03.028> PMID: 16828517
- [34] Taylor B, Rochtchina E, Wang JJ, *et al.* Body mass index and its effects on retinal vessel diameter in 6-year-old children. *Int J Obes* 2007; 31(10): 1527-33. <http://dx.doi.org/10.1038/sj.ijo.0803674> PMID: 17607323
- [35] Liang C, Gu C, Wang N. Retinal Vascular Caliber in Coronary Heart Disease and Its Risk Factors. *Ophthalmic Res* 2023; 66(1): 151-63. <http://dx.doi.org/10.1159/000526753> PMID: 36044871
- [36] Xiao W, Gong W, Chen Q, Ding X, Chang B, He M. Association between body composition and retinal vascular caliber in children and adolescents. *Invest Ophthalmol Vis Sci* 2015; 56(2): 705-10. <http://dx.doi.org/10.1167/iovs.14-14946> PMID: 25574054
- [37] Ciumărnean L, Milaciu MV, Negrean V, *et al.* Cardiovascular Risk Factors and Physical Activity for the Prevention of Cardiovascular Diseases in the Elderly. *Int J Environ Res Public Health* 2021; 19(1): 207. <http://dx.doi.org/10.3390/ijerph19010207> PMID: 35010467
- [38] Li LJ, Kramer M, Tapp RJ, *et al.* Gestational diabetes mellitus and retinal microvasculature. *BMC Ophthalmol* 2017; 17(1): 4. <http://dx.doi.org/10.1186/s12886-016-0398-7> PMID: 28100181
- [39] Benitez-Aguirre PZ, Sasongko MB, Craig ME, *et al.* Retinal vascular geometry predicts incident renal dysfunction in young people with type 1 diabetes. *Diabetes Care* 2012; 35(3): 599-604. <http://dx.doi.org/10.2337/dc11-1177> PMID: 22250064

**DISCLAIMER:** The above article has been published, as is, ahead-of-print, to provide early visibility but is not the final version. Major publication processes like copyediting, proofing, typesetting and further review are still to be done and may lead to changes in the final published version, if it is eventually published. All legal disclaimers that apply to the final published article also apply to this ahead-of-print version.