



The Open Ophthalmology Journal

Content list available at: <https://openophthalmologyjournal.com>



CASE REPORT

Epinucleus Scraping: Safe New Phacoemulsification Technique for Rock-Hard Cataracts

Aki Kondo^{1*}, Mari Goto², Tatsuya Mimura³, Shunichi Tanaka⁴ and Masao Matsubara⁵

¹Ando Eye Clinic, Kanagawa, Japan

²Department of Ophthalmology, Tokyo Metropolitan Cancer and Infectious Diseases Center Komagome Hospital, Tokyo, Japan

³Department of Ophthalmology, Teikyo University, Tokyo, Japan

⁴Shimizu Eye Clinic, Tokyo, Japan

⁵Yaesu Sakura Eye Clinic, Tokyo, Japan

Abstract:

Introduction:

Phacoemulsification of rock-hard cataracts is challenging because the leathery epinucleus at the posterior plate often found in such cataracts tends to prevent smooth dissection of the nucleus. We devised an Epinucleus scraping technique to overcome this problem.

Methods:

The epinucleus is initially stripped of the hard endonucleus using a new instrument. The isolated endonucleus can then be readily chopped and divided with a phaco chopper or in the usual manner.

Conclusion:

Phacoemulsification of rock-hard cataracts can be carried out safely and easily with epinucleus scraping technique.

Keywords: Cataract surgery, Rock-hard cataract, Phacoemulsification, Epinucleus, Endonucleus, Phaco chopper.

Article History

Received: May 14, 2020

Revised: December 8, 2020

Accepted: December 25, 2020

1. INTRODUCTION

Phacoemulsification of rock-hard cataracts is challenging because the dissection of these cataracts is often very difficult, and the sharp edges of hard nuclear fragments can easily damage the posterior capsule or corneal endothelium during surgery. To effectively remove rock-hard cataracts, we need to consider factors related to phacoemulsification, including the ultrasound mode, fluidics, and vacuum system, as well as the surgical technique.

Performing safe and effective phacoemulsification of rock-hard cataracts with the conventional chopping technique remains a challenge for the following reasons. First, a leathery epinucleus at the posterior plate is often found in patients with rock-hard cataracts. This tends to hinder smooth dissection of the nucleus, since chopped fragments often retain posterior bridging strands that keep nuclear fragments attached to each

other [1]. Second, even after successful dissection, the sharp edges of hard nuclear fragments may contact the thin weak posterior capsule and rupture it during procedures like rotation. Third, the corneal endothelium can be damaged by uncontrolled hard nuclear fragments. Techniques for dividing rock-hard cataracts described in the literature, such as ‘decrease and conquer’ or ‘phaco forward-chop’, do not overcome these problems [2 - 4].

Therefore, we devised the epinucleus scraping method and developed an epinucleus scraper for the safer division of rock-hard cataracts. The lens is structurally composed of radiating fibers, and multiple layers form rings surrounding the central nucleus (Fig. 1). The phaco chop method utilizes the radiating fiber structure when dissecting the nucleus. On the other hand, our epinucleus scraping method utilizes the annular layer structure surrounding the central nucleus, and we developed an epinucleus scraper to facilitate separation of the layers. The small, thin and round tip of the instrument enables simple insertion between layers and easy dissociation (Fig. 2). After

* Address correspondence to this author at the Ando Eye Clinic 965-1 Souryo Matsuda Kamiashigara Kanagawa, Japan; Tel: +81-465834545; E-mail: aki94088@hotmail.com

the epinucleus is stripped off the hard endonucleus using the epinucleus scraper, the isolated endonucleus can be readily chopped and divided with a phaco chopper or in the usual manner, after which phacoemulsification can be carried out safely and easily.

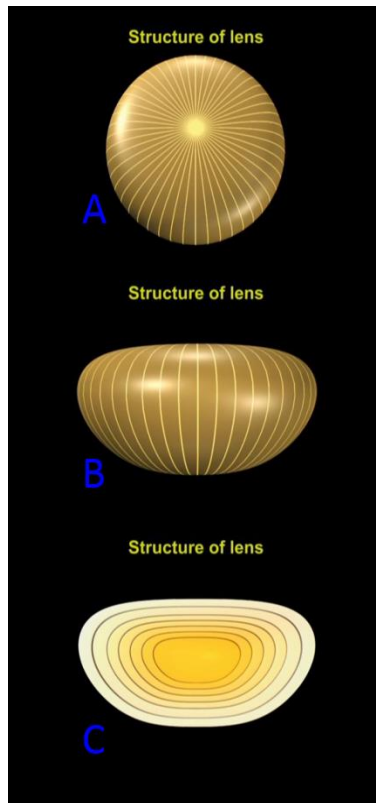


Fig. (1). The lens is composed of radial fibers (A: anterior view, B: lateral view) and multiple layers surround the central nucleus resembling rings (C: lateral view).




Fig. (2). Epinucleus scraper: A novel instrument developed in order to facilitate separation of the layers of the lens. The small and thin tip of the instrument enables simple insertion and easy dissociation of layers.

2. MATERIALS AND METHODS

Surgery is commenced by making a temporal clear corneal incision with a 3.0 mm slit knife (MANI® Ophthalmic Knife) under topical anesthesia with 4% lidocaine hydrochloride ophthalmic solution. A side-port incision is made on the superior side in the right eye and the inferior side in the left eye with a 30.0 degrees straight knife (MANI® Ophthalmic Knife). When the cataract is white with a hard nucleus, the anterior capsule must be visualized using trypan blue staining [5]. After washing out excess trypan blue with irrigation and aspiration,

the anterior chamber is filled with an ophthalmic viscosurgical device (1.0% hyaluronate sodium, Opegan-Hi®). The anterior capsule is then opened by continuous curvilinear capsulorhexis [6] using forceps, and hydrodissection is performed meticulously to avoid the Capsular Block Syndrome (CBS).

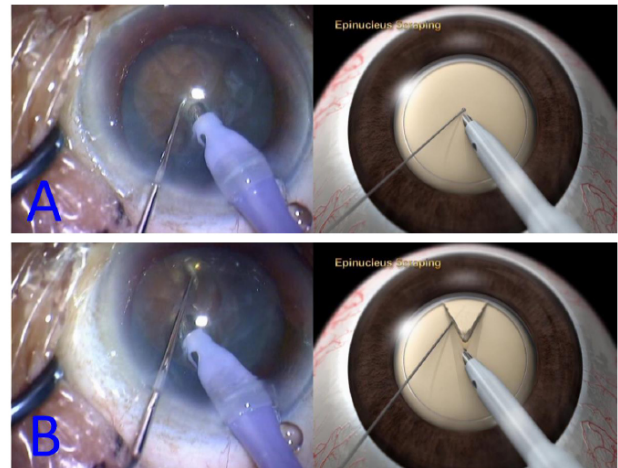


Fig. (3). Photographs and diagram of the epinucleus scraping technique. The epinucleus scraper is inserted between the central nucleus and epinucleus (A) and is used to scrape the surface of the epinucleus in the equatorial direction (B).

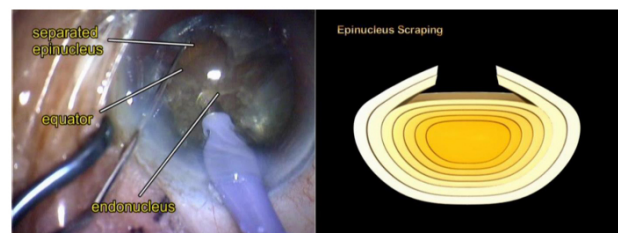


Fig. (4). After circumferential separation of the epinucleus is completed, the equatorial portion of the hard endonucleus can be clearly recognized.

Using the Infinity Vision System (Alcon, Inc. Tokyo, Japan), a bevel down 30-degree straight tip is driven into the lens and kept in position to stabilize the lens. Using the other hand, the epinucleus scraper is introduced from the side port at 45 degrees to the main incision, and its tip is inserted between the central nucleus and epinucleus to scrape the surface of the epinucleus in the equatorial direction, thus separating the epinucleus from the central nucleus (Fig. 3). This procedure is performed repeatedly while the nucleus is rotated 360 degrees, and 30-60 degrees can be scraped each time. After treating the lens for 360 degrees, the tip of the epinucleus scraper is inserted deeper into the lens on the second round, and the same procedure is repeated. The procedure is repeated further until all layers of the epinucleus have been stripped off the hard endonucleus. After this has been achieved, the equatorial portion of the endonucleus can be clearly recognized (Fig. 4). As the endonucleus becomes harder, the epinuclear layer that can be stripped in one round become thinner and the procedure has to be repeated more often. If the endonucleus is very dense, 6 or 7 rounds may be needed. Complete separation of the endonucleus and epinucleus is hard to achieve by this

procedure and is not necessary, especially in the posterior portion. As long as the epinucleus is separated from the endonucleus around the equator by the scraper, we can proceed with completing their separation. Phacoemulsification of the isolated endonucleus is then carried out in the usual manner. After the hard endonucleus has been removed, the epinucleus can be clearly seen protecting the capsule (Fig. 5). Subsequently, the epinucleus is aspirated from the central area toward the periphery.

Phacoemulsification is followed by irrigation and aspiration of the cortex, insertion of an ophthalmic viscosurgical device (1.0% hyaluronate sodium, Opegan-Hi®), and insertion of a posterior chamber Intraocular Lens (IOL) inside the bag. After the IOL is positioned in the capsular bag, the ophthalmic viscosurgical device is removed. At the end of surgery, the anterior chamber is reformed by hydrating the incision borders with 0.184 mg/ml oxiglutatione (Opeguard neokit®).

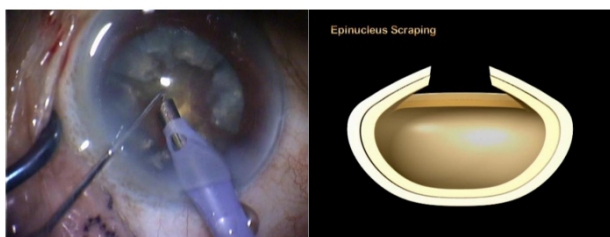


Fig. (5). After the hard endonucleus is removed, the epinucleus can be seen protecting the capsule like a shell.

3. RESULTS

We performed the epinucleus scraping method on 9 patients with rock-hard cataracts from January 2014 to October 2019, with no complications such as a ruptured posterior capsule or bullous keratopathy after surgery. Thus, the epinucleus scraping method achieves safe phacoemulsification.

4. DISCUSSION

Anatomically, the human lens consists of 3 distinct structures: the capsule, the cortex, and the nucleus. These structures form a mass composed of a number of lamellar zones. The fetal nucleus is the most centrally located structure, and it becomes a harder central nucleus as new fibers are laid down over time. The new fibers join each other radially and form a Y-shaped line anteriorly and posteriorly [7, 8]. Conventional nucleofractis techniques were developed to crack the lens along the radial plane where the fibers join. The conventional technique is useful for managing moderate nuclear cataracts. However, in some patients with dense brunescant cataracts, especially rock-hard cataracts, a complete nuclear division is not easy using conventional techniques because the radial plane of the cataract develops strong adhesions around the posterior epinucleus [7, 9], which means that nuclear fragments remain attached to each other. When the nucleofractis technique is performed for a rock-hard nucleus, complete division of the nucleus is essential for an efficient and safe operation, while incomplete fragmentation may lead to undesirable outcomes.

Our epinucleus scraping technique involves the circumferential separation of the epinucleus from the endonucleus utilizing the lamellar structure of layers surrounding the central nucleus. After the hard endonucleus has been separated from the leathery posterior plate and reduced in size, it can be dissected relatively easily. Meanwhile, the separated epinucleus acts like a protective shell that guards the posterior capsule against the sharp edges of the nucleus and avoids capsular rupture. If there are weak zonules and anterior vitreous detachment following Wieger ligament rupture, which means that the posterior capsule tends to rise up, the separated epinucleus holds the posterior capsule down and enables safe phacoemulsification.

The epinucleus with a leathery posterior plate may sometimes be tough and highly viscous, making dissection or phacoemulsification difficult. However, it has been separated from the hard endonucleus and is smaller in size, so dissection is much easier than dissecting an intact rock-hard cataract. Dissection of the epinucleus may be performed by bimanual tearing using a phaco chopper and ultrasound tip, or by cutting it into pieces with surgical scissors inside the anterior chamber or in the bag.

This paper has only a few cases over a five year period, presented by a single surgeon. The paper is written in a proprietary manner, more or less to emphasize the new instrument as well as a particular surgeon's technique. There is a lack of institutional oversight as well.

CONCLUSION

We devised the epinucleus scraping method and developed an epinucleus scraper for the safer division of rock-hard cataracts. Our method has three advantages over standard phacoemulsification for rock-hard cataracts. First, it facilitates the handling of the posterior leathery plate and rock-hard central nucleus. Second, it protects the posterior capsule and avoids rupture by sharp nuclear fragments. Third, the endothelium is protected from damage by nuclear fragments. By adopting this technique, better surgical outcomes can be expected in patients with rock-hard cataracts. However, as this is a new instrument, further evaluation by other cataract surgeons is required.

ETHICS APPROVAL AND CONSENT TO PARTICIPATE

This study was approved by the Institutional Review Board of Tokyo Women's Medical University, Japan under ethical approval no. 2611.

HUMAN AND ANIMAL RIGHTS

Not applicable.

CONSENT FOR PUBLICATION

Not applicable.

AVAILABILITY OF DATA AND MATERIALS

The data that support the findings of this study are available from the corresponding author, [A.K.] upon

reasonable request.

FUNDING

None.

STANDARDS OF REPORTING

CARE guidelines have been followed.

CONFLICT OF INTEREST

The authors declare no conflict of interest, financial or otherwise.

ACKNOWLEDGEMENTS

Declared none.

REFERENCES

- [1] Gimbel HV. Principles of nuclear phacoemulsification. *Cataract Surgery; Techniques, Complications, and Management*. 2nd ed. Philadelphia, PA: Saunders 2004; pp. 154-81.
- [2] Kim HK. Decrease and conquer: Phacoemulsification technique for hard nucleus cataracts. *J Cataract Refract Surg* 2009; 35(10): 1665-70. [<http://dx.doi.org/10.1016/j.jcrs.2009.05.038>] [PMID: 19781457]
- [3] Kamoi K, Mochizuki M. Phaco forward-chop technique for managing posterior nuclear plate of hard cataract. *J Cataract Refract Surg* 2010; 36(1): 9-12. [<http://dx.doi.org/10.1016/j.jcrs.2009.07.047>] [PMID: 20117699]
- [4] Vanathi M, Vajpayee RB, Tandon R, Titiyal JS, Gupta V. Crater-and-chop technique for phacoemulsification of hard cataracts. *J Cataract Refract Surg* 2001; 27(5): 659-61. [[http://dx.doi.org/10.1016/S0886-3350\(00\)00702-1](http://dx.doi.org/10.1016/S0886-3350(00)00702-1)] [PMID: 11377891]
- [5] Melles GRJ, de Waard PWT, Pameyer JH, Houdijn Beekhuis W. Trypan blue capsule staining to visualize the capsulorhexis in cataract surgery. *J Cataract Refract Surg* 1999; 25(1): 7-9. [[http://dx.doi.org/10.1016/S0886-3350\(99\)80004-2](http://dx.doi.org/10.1016/S0886-3350(99)80004-2)] [PMID: 9888070]
- [6] Gimbel HV, Neuhann T. Development, advantages, and methods of the continuous circular capsulorhexis technique. *J Cataract Refract Surg* 1990; 16(1): 31-7. [[http://dx.doi.org/10.1016/S0886-3350\(13\)80870-X](http://dx.doi.org/10.1016/S0886-3350(13)80870-X)] [PMID: 2299571]
- [7] Gimbel HV. Principles of nuclear phacoemulsification. *Cataract Surgery; Techniques, Complications, and Management*. 2nd ed. Philadelphia, PA: Saunders 2004; pp. 154-81.
- [8] Smith GTH, Smith RC, Brown NAP, Bron AJ, Harris ML. Changes in light scatter and width measurements from the human lens cortex with age. *Eye (Lond)* 1992; 6(Pt 1): 55-9. [<http://dx.doi.org/10.1038/eye.1992.10>] [PMID: 1426401]
- [9] Steinert RF. Phaco chop. *Cataract Surgery; Techniques, Complications, and Management*. 2nd ed. Philadelphia, PA: Saunders 2004; pp. 183-91.

© 2021 Kondo *et al.*

This is an open access article distributed under the terms of the Creative Commons Attribution 4.0 International Public License (CC-BY 4.0), a copy of which is available at: <https://creativecommons.org/licenses/by/4.0/legalcode>. This license permits unrestricted use, distribution, and reproduction in any medium, provided the original author and source are credited.