

HRT for the Diagnosis and Detection of Glaucoma Progression

Jessica S. Maslin¹, Kaweh Mansouri² and Syril K. Dorairaj^{*,3}

¹*Ophthalmology and Visual Science, Yale University School of Medicine, New Haven, CT, USA*

²*Division of Ophthalmology, Department of Clinical Neurosciences, Geneva University Hospitals, Geneva, Switzerland*

³*Department of Ophthalmology, Mayo Clinic, Jacksonville, FL, USA*

Abstract: Confocal scanning laser ophthalmoscopy through the Heidelberg Retina Tomograph (HRT) provides a rapid, safe, noncontact, and noninvasive imaging of the optic disc in three-dimensions, and provides precise detailed information about the optic disc beyond that which the clinical exam can measure. The HRT I was developed for research purposes only and was not used clinically. The HRT II was developed to be user-friendly, more rapid, and was used as an adjunct to clinical examination in the detection and progression of glaucoma. One of the main pitfalls of the HRT II was that it was operator-dependent. The HRT III was developed to be operator-independent. Initially the Moorsfield Regression Analysis provided the analysis of the stereometric optic disc parameters. The Glaucoma Probability Score, given its ease of use, operator-independence, and rapidity of use, soon gained popularity. Numerous studies have compared these two methods of analysis, with the conclusion that the Glaucoma Probability Score provides a higher sensitivity and a lower specificity than the Moorsfield Regression Analysis, which may indicate that it has potential as a screening test for glaucoma. However, there is no consensus on the use of the Glaucoma Probability Score as a screening test for glaucoma. While HRT data may be useful as a clinical adjunct in the screening and diagnosis of glaucoma, it should ultimately only be used to support clinical examination.

Keywords: Glaucoma, Heidelberg retina tomograph, retinal nerve fiber layer, topographic change analysis.

INTRODUCTION

Glaucoma is an optic neuropathy with characteristic visual field loss. Intraocular pressure (IOP) is the most important risk factor and cause of nerve damage and subsequent visual field loss. Glaucoma is a chronic disease that must be longitudinally assessed and treated based on the appearance of the optic nerve and an evaluation of its function. Prior to the advent of confocal scanning laser ophthalmoscopy, the detection of progressive glaucomatous change in the optic disc was primarily done through clinical examination and optic disc photos. This method not only had high inter- and intra-observer variability, but poor reproducibility as well [1]. Accurate documentation of the appearance of the disc is critical for the management of glaucoma. Confocal scanning laser ophthalmoscopy through the Heidelberg Retina Tomograph (Heidelberg Engineering, Heidelberg, Germany) provides a rapid, safe, noncontact, and noninvasive imaging of the optic disc in three-dimensions, and provides precise detailed information about the optic disc beyond that which the clinical exam can measure. The HRT has been utilized as an adjunct to the clinical exam to aid in the diagnosis and management of glaucoma.

BACKGROUND OF THE HEIDELBERG RETINA TOMOGRAPH

The HRT utilizes a 67 nm diode laser and two oscillating mirrors to ultimately create a layered 3-dimensional image. The

first commercial confocal scanning laser ophthalmoscope (Laser Tomographic Scanner, Heidelberg) was built and tested in the 1980s. The first version of the HRT, developed in 1991, was based on improvements to this model and was primarily used for research. By 1999, even more improvements to the first version HRT allowed the second version, known as the HRT II, to become widely accepted in clinical use. The HRT II was more user-friendly, with fine focus and scan depth automated, and able to be used in the routine clinical setting [1]. The HRT III was developed recently and included even more user-friendly additions.

There are numerous advantages to the HRT over clinical exam. The variability between the optic disc area can often lead to difficulty identifying nerves with glaucomatous damage as physiologically small discs that have a cup/disc ratio can be as small as 0.3 and have damage, while a physiologically large disc (macro disc) may have a cup/disc as high as 0.9 without any presence of glaucomatous damage. Optic disc size is an important consideration when evaluating for glaucoma [2]. The HRT precisely measures the disc area and helps identify physically small or large discs, which may confound a clinical diagnosis. The neuroretinal rim is characterized by a pattern to its expected thickness, known as the ISNT rule [3]. The ISNT rule can be checked with the HRT sector data, as violation of this rule is often a sign of glaucomatous nerve damage [4].

We will review the background on the HRT II and the HRT III below.

*Address correspondence to this author at the Mayo Clinic, 4500 San Pablo Road, Jacksonville, FL 32224, USA; Tel: 904-953-2377; Fax: 904-953-7040; E-mail: dorairaj.syril@mayo.edu

HRT II

Compared to the original HRT (HRT I), the HRT II provides greater automation of image acquisition, standardizes many aspects of the imaging process, and has software that is able to provide clinically valuable automated analysis not seen in with the HRT I. The HRT I used 3 field size settings ($10^\circ \times 10^\circ$, $15^\circ \times 15^\circ$, or $20^\circ \times 20^\circ$) centered on the optic nerve, with a resolution of 256×256 pixels [1]. The fine focus and scan depth had to be adjusted manually using the original HRT. The HRT II uses a higher resolution at 384×384 pixels and measures a 15° scan area [1]. Unlike the original HRT, the HRT II automatically adjusts the fine focus and scan depth. While the longitudinal resolution varies with the scan depth in the HRT I, the HRT II keeps the axial resolution of the scan at $62 \mu\text{m}$ by varying the number of imaging planes. This allows for a constant digital resolution of both the transverse axis and longitudinal axis despite individual differences in the depth or size of the optic disc.

An HRT II imaging session typically includes the pre-scan and three confocal scans, all of which take usually around 7 seconds. The reflectance image of the optic disc, with the lightest area at the base of the cup, obtained by the HRT is a useful tool to use in drawing the contour line around the disc margin. This contour line must be manually drawn by the operator of the HRT. The topographic image of the optic disc is a 3-dimensional image in which the dark colors are elevated and light colors appear deeper (Fig. 1). Red indicates the cup, while the blue and green areas demonstrate the sloping and nonsloping neuroretinal rim, respectively (Fig. 1). The HRT II software automatically places a reference plane that approximates the lowest extent of the nerve fiber layer. The cup is considered to be the area that falls below this reference plane, while the rim is considered to be the area above the reference plane (as seen

in Fig. 1).

The HRT II calculates stereometric parameters, including cup shape, cup volume, rim area, rim volume, mean retinal nerve fiber layer (RNFL) thickness, mean height of contour, mean contour elevation, mean cup depth, and mean height inside contour line, and compares them to the normal ranges [1]. Topographic change analysis (TCA) is a statistical method that compares topographic values in discrete areas (4×4 pixels, also known as a “superpixel”) of the image and utilizes a comparison of each follow-up image to its baseline. TCA utilizes raw topography values rather than a reference plane or contour line to compute at each “superpixel” whether the change in height values between two time points could occur by chance alone. A low probability ($P < 0.05$) would indicate that the change is likely to be real rather than not. The HRT automatically performs the TCA if there is one mean baseline image and at least two follow-up images. TCA is a powerful analysis that can often detect very small changes in the optic disc tomography. A study by Chauhan demonstrated that significant progression was classified using a cutoff of 95th percentile ($P < 0.05$, meaning less than 5% of healthy control subjects had significant change) in a 20 superpixel area [5].

While there have been several different mathematical algorithms developed in order to best use all these measurements to differentiate between glaucomatous eyes and healthy eyes, the Moorfields Regression Analysis (MRA) is the analysis provided by the HRT II, and it compares the topography of the optic disc to that of a normative database. An advantage of the MRA is that it can be used to compare the neuroretinal rim areas in six sectors to the corresponding areas of visual field and provide a global comparison of the data [1]. The six different sectors of the neuroretinal rim that are used for comparison are: superior half of disc, inferior half of disc, superior temporal segment, inferior temporal segment, superior segment, and

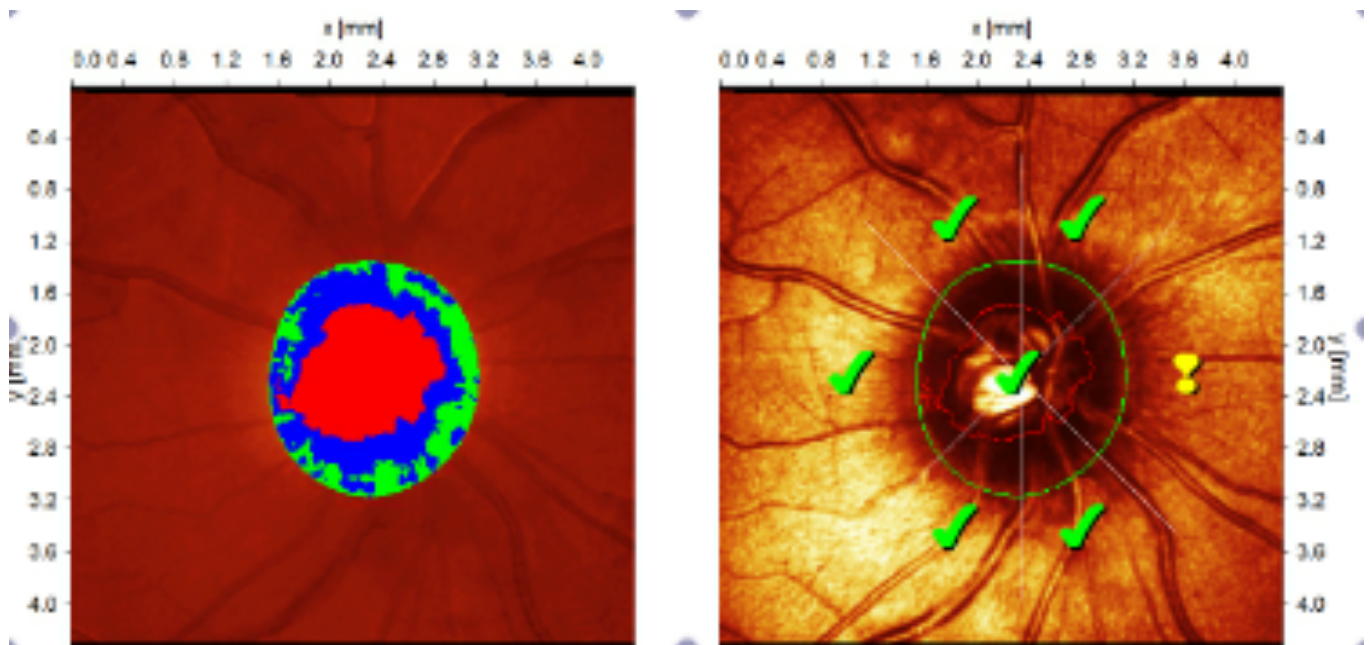
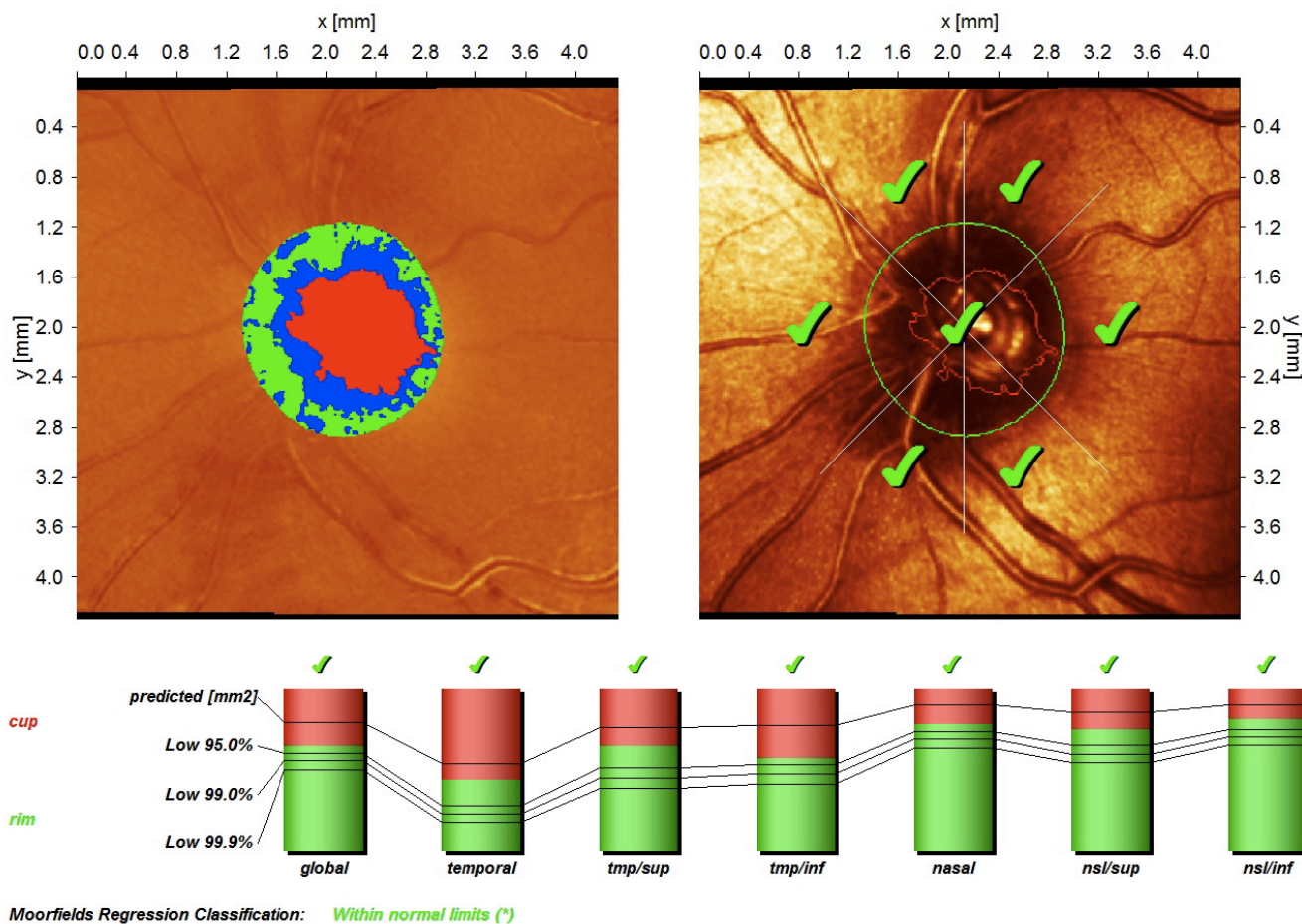


Fig. (1). Topographic map of the optic disc. Dark colors are elevated and light colors appear deeper. Red indicates the cup, while the blue and green areas demonstrate the sloping and nonsloping neuroretinal rim, respectively.



(*) Moorfields regression classification (Ophthalmology 1998;105:1557-1563). Classification based on statistics. Diagnosis is physician's responsibility.

Rim Area	global	temporal	tmp/sup	tmp/inf	nasal	nsl/sup	nsl/inf
actual [mm2]	1.41	0.23	0.18	0.16	0.41	0.21	0.22
predicted [mm2]	1.71	0.29	0.22	0.22	0.47	0.23	0.24
low 95.0% CI lim. [mm2]	1.31	0.15	0.15	0.15	0.38	0.18	0.20
low 99.0% CI lim. [mm2]	1.20	0.12	0.13	0.14	0.36	0.16	0.19
low 99.9% CI lim. [mm2]	1.09	0.10	0.11	0.12	0.33	0.15	0.17
actual/disc area [%]	65.56	44.30	65.34	57.35	78.51	75.19	81.51
predicted [%]	79.62	54.36	76.50	77.78	90.56	85.65	90.52
low 95.0% CI lim. [%]	60.84	28.43	51.36	53.62	73.71	65.44	74.90
low 99.0% CI lim. [%]	55.89	23.17	45.30	47.69	69.08	60.12	70.54
low 99.9% CI lim. [%]	50.63	18.26	39.13	41.60	64.05	54.46	65.81

Fig. (2). An example of the MRA as utilized by the HRT II in a nonglaucomatous nerve. MRA compares the sectoral neuroretinal rim areas to the corresponding areas of the visual field in six different sectors, as shown in the analysis at the bottom of the figure.

inferior segment [1]. As glaucoma tends to affect the inferior-temporal and superior-temporal areas of the disc more than the nasal and temporal sectors, this is a useful tool to detect early axonal loss in these particular sectors. An example of an MRA analysis with the described sectoral analysis is shown in Fig. (2).

Structural damage may precede functional damage in glaucoma [6-10], with the neuroretinal rim being especially sensitive [11-14]. HRT has been shown to be useful in the

clinical setting in detecting structural damage before any functional damage has manifested itself [15, 16]. A prospective study by Larrosa *et al.* found that the temporal-inferior and temporal-superior sectors on the MRA are highly predictive for the onset of visual field loss in glaucoma suspects [17]. Brigatti and Caprioli found stronger correlations with the HRT between optic disc parameters and visual fields [18]. Lee *et al.* along with Iester found that the highest correlation in the HRT stereometric parameters were between rim area and mean deviation on the visual field [19-

21]. A study by Tole *et al.* demonstrated that this correlation was seen for the entire circumference of the disc except for the directly temporal segment [22]. This correlation also extends to short-wavelength automated perimetry visual fields [23-25].

The normative database used in the MRA is derived from measurement data taken from a group of 112 normal Caucasian eyes, but the decision as to whether “outside normal limits” represents “glaucoma” is ultimately a clinical decision. It is important to keep in mind that in the MRA normative database, all subjects were Caucasian, with ametropia of < 6 diopters and an optic disc size of between 1.2-2.80mm² [26]. The OHTS CSLO Ancillary study found that African American patients had significantly larger mean optic discs, cups, neuroretinal rims, cup/disc ratios, and smaller mean rim/disc ratios than other nonblack patients [27]. This study also suggested that racial differences in the optic disc tomography parameters could be mostly explained by the larger mean optic disc size in African American patients compared to nonblack patients [2]. While studies have suggested that the MRA may have similar specificity in black Americans as white Americans [28], the MRA classification should be used with caution in patients who are nonwhite as there may be racial differences in normative values. The MRA classification should also be used with caution in patients who have optic disc size greater than 2.80mm² or less than 1.20 mm², or in patients with high refractive error. In particular, Iester *et al.* demonstrated that the sensitivity and specificity of HRT tends to be lower in very small discs [21].

HRT has been shown to have high reproducibility and accuracy in determining optic disc topography [29]. The sensitivity and specificity were found to be affected by reference height difference and image quality, the same factors that affect the measurement variability of the HRT [30]. There is variability of topographic measurements that can decrease the ability of the stereometric parameters to detect glaucomatous progression [31-34].

It is well known that the neuroretinal rim area is related in physiological terms to the optic nerve head size [35], and the MRA makes use of the logarithmic transformation of this data in order to define the normal ranges. The European Glaucoma Prevention Study (EGPS) HRT ancillary study was one of the largest studies to be performed on ocular hypertensive patients and demonstrated that there were significant associations between HRT topographic measurements and stereophotographic assessments of vertical Cup Disc ratio (CDR), HRT disc area, and pattern standard deviation (PSD) [36].

The HRT II uses the MRA report in order to compare the neuroretinal rim area to normal ranges at 50%, 95%, 99% and 99.9% confidence intervals (CI). A green check appears if they are within the 95% CI, a yellow exclamation mark if they are between the 95%-99.9%, and a red X if outside the 99.9% CI. An example of this classification is shown on a topographic map of the optic nerve (Fig. 1). At certain measurements of the neuroretinal rim area, the MRA classifies as “borderline” as there is uncertainty as to whether or not these measurements fall within the normal range.

In utilizing one estimate of glaucoma prevalence from the Blue Mountain Eye Study in Australia (estimated at 2.4%)[37], a predicted estimate of the borderline cases amounted to only 4%. In these cases, it is predicted that, given the larger number of normal eyes than glaucomatous eyes in a given population, the misclassification rate is about 7% and would ultimately result in more normal subjects being classified as “outside normal limits” than the other way around. In a typical referral population, where the prevalence of glaucoma may be as high as 30%, about 37% of the cases that are classified as borderline are predicted to have true glaucoma [1]. The most common cause of false negatives occurs from shallow cupping due to parapapillary atrophy, but this is often evident on clinical examination.

In the clinical setting, the interpretation of a patient’s HRT printout must be taken carefully and in steps [1].

1. First, note the mean topography standard deviation (SD) in order to check the image quality. Quality is considered good if the SD is less than 30 um. The test should be repeated if the SD is greater than 40 um.
2. Next, review the position of the contour line.
3. Review the stereometric parameters and topography map of the optic disc.
4. Review the global and sector classification based on the MRA.

HRT III

The latest version of the HRT is HRT III, in which the optic nerve head and its surrounding RNFL is automatically fitted to that of a model optic disc [38]. It provides an analysis of the topography without a contour line placement [38] and thus does not require use of an operator. This version of the HRT, which includes the operator-independent glaucoma probability score (GPS) instead of the MRA, uses an enlarged database that includes 733 patients of Caucasian descent, 215 patients of African descent, and 100 Indian participants. In addition, unlike the MRA, the GPS utilizes the whole topographic image of the optic disc, including the cup size, cup depth, rim steepness, and horizontal/vertical RNFL curvature whereas the MRA uses only a logarithmic relationship between the neuroretinal rim and optic disc areas. Fig. (3) shows an example of a GPS analysis of a glaucomatous right optic nerve using these parameters. The GPS was found to be a highly reproducible diagnostic tool, with image quality being the main factor influencing reproducibility [39]. There has not been a consensus in the literature on whether or not glaucomatous or healthy discs are associated with an improved reproducibility. One study found the best reproducibility was in healthy patients [39]. Another study demonstrated that test-retest repeatability tended to improve with an increase in cup/disc ratio, which seems to suggest the opposite [40].

According to numerous studies, the diagnostic accuracy of the HRT III in distinguishing glaucomatous eyes from healthy eyes is comparable to that of a glaucoma specialist [41], and similar to those of prior HRTs [42-44].

Quality: **Very good** (SD 12 μm)

Initial Report

Quality: **Good** (SD 22 μm)

Focus: 3.00 dpt

Focus: 3.00 dpt

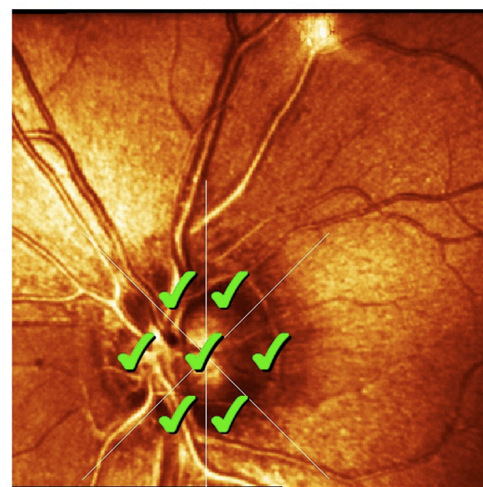
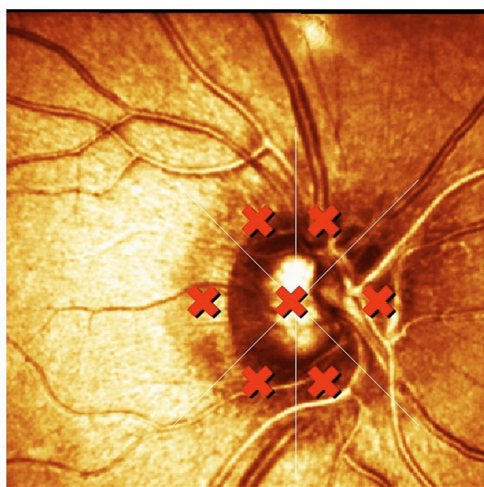
Operator: UNNISA

Operator: UNNISA

OD

OS

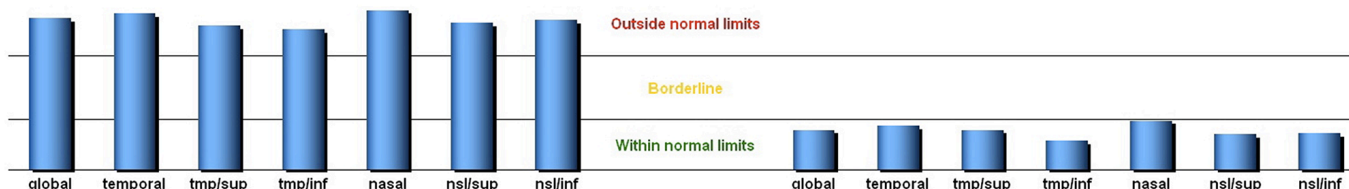Glaucoma Probability Score (GPS)



global	temporal	tmp/sup	tmp/inf	nasal	nsi/sup	nsi/inf	Parameter	global	temporal	tmp/sup	tmp/inf	nasal	nsi/sup	nsi/inf
0.85	0.87	0.80	0.78	0.89	0.82	0.83	Glaucoma prob.	0.22	0.24	0.22	0.16	0.27	0.20	0.20
0.11	-0.10	-0.32	-0.23	0.58	0.18	-0.04	Rim steepness	0.43	0.25	-0.02	0.18	0.80	0.23	0.28
0.46	0.12	0.08	0.07	0.07	0.07	0.07	Cup size [mm ²]	0.32	0.13	0.08	0.06	0.03	0.05	0.05
0.55	---	---	---	---	---	---	Cup depth [mm]	0.46	---	---	---	---	---	---
-0.08	---	---	---	---	---	---	H. RNFL curv.	-0.03	---	---	---	---	---	---
-0.16	---	---	---	---	---	---	V. RNFL curv.	-0.15	---	---	---	---	---	---

✘ ✘ ✘ ✘ ✘ ✘ ✘

✔ ✔ ✔ ✔ ✔ ✔ ✔



Glaucoma Probability Score Classification:

Outside normal limits

Glaucoma Probability Score Classification:

Within normal limits

✔	Within normal limits
?	Borderline
✘	Outside normal limits

Comments:

Signature:

Date: 02/01/2014

Software Version: 3.2/88
www.HeidelbergEngineering.com

Fig. (3). An example of the GPS as utilized by the HRT III in a glaucomatous nerve. Full analysis of optic nerve topography parameters and sectoral analysis as well. In addition, compared to the MRA, GPS is operator independent.

An advantage of the GPS classification is that while quality affects individual GPS parameters, it does not affect the overall GPS [39]. Unlike stereometric parameters [21, 45], reproducibility of GPS is not affected by refraction, disc size, disc characteristics like paripapillary atrophy or tilting, or disease stage [39]. Borderline cases tend to have the poorest reproducibility in GPS [46]. Prior studies have

shown that GPS has a sensitivity of over 70% and a specificity of over 90% in Caucasian eyes [47-50].

COMPARISON OF GPS AND MRA

Several studies have been done to evaluate the diagnostic performance of the GPS compared to the MRA in

differentiating glaucomatous eyes from healthy eyes [47-49]. The results have shown that the performance is essentially equal and thus GPS is a useful glaucoma screening device given its ease of use compared to the HRT II MRA.

A retrospective observational study by Reddy *et al.* compared the agreement, sensitivity, and specificity of the HRT III GPS and MRA across the spectrum of glaucomatous visual field loss using data from 247 glaucoma patients and 142 controls [51]. They found that age-adjusted specificity was 92% and 93% for the GPS and MRA, respectively, with a respective sensitivity of 76.88% and 80.85%. The discrimination capability was statistically better in the moderate glaucoma group using GPS rather than MRA ($P < 0.001$) [51].

Global parameter sensitivity and specificity values are similar between GPS and MRA [45-47]. In one of the earliest studies comparing GPS to MRA, Yip *et al.* retrospectively analyzed data from healthy and glaucomatous eyes in Caucasian patients and concluded that while GPS had similar diagnostic performance as MRA, its sensitivity was higher and specificity was lower [52]. In a small study, Jindal *et al.* compared GPS and MRA in 50 healthy eyes and 50 early glaucomatous eyes [53]. He found that GPS tended to have higher sensitivities, lower specificities, and lower likelihood ratios than the MRA. Both GPS and MRA showed decreased sensitivity for smaller discs. GPS showed decreased specificity as well for larger discs [53]. One study by Bozkurt *et al.* compared MRA and GPS in primary open angle glaucoma risk (POAG) eye and healthy eyes in a Turkish population [54]. They found that the GPS automated classification showed a similar sensitivity to MRA (89.2% to 81.0%, respectively), but a considerably lower specificity (57.6% compared to 75.0%) [54]. This trend was validated when a similar comparison was applied to an Indian population [55]. However, a study by Saito found that, while the sensitivity and specificity of GPS to detect glaucoma were similar to MRA in a Japanese population, the specificity tended to be lower than that of a white population [56], suggesting racial differences may be present. A report published by Kamdeu Fansi *et al.* investigated the validity of GPS compared to MRA in detecting glaucomatous nerve damage in a screening population of 221 high-risk eyes [57]. They discovered that GPS appears to be more sensitive and less specific in detecting glaucoma. The ability of GPS and

MRA to detect glaucoma was also compared in a group of highly myopic eyes and healthy eyes, and it was shown that the tendency of GPS to have a higher sensitivity but lower specificity also applied to highly myopic patients [58].

These above studies all seem to suggest that GPS may have better usage as a glaucoma screening tool than MRA. However, when comparing GPS and MRA in a cross-sectional study, Saito found that neither GPS nor MRA had sufficient sensitivity to be used in a population-based setting to detect glaucoma, though its specificity was sufficient [59]. This was in contrast to prior hospital-based studies. Many previous studies have reported the diagnostic ability of HRT III in a hospital-based population. Although the results vary among the reports, a moderate sensitivity (MRA: 40%–74%, GPS: 58%–71%) [48, 60, 61] and a fairly high specificity (MRA: 87%–93%, GPS: 66%–94%) [48, 60, 61] have been reported in mostly Caucasian eyes. In this case, a population-based setting was considered more representative of a screening glaucoma population. A comparison between the sensitivities and specificities of the MRA and GPS, as demonstrated by prior published studies, is shown in Table 1.

The Singapore Malay Eye Study investigated the agreement between the stereometric parameters in HRT II and those in HRT III in a normal Asian population (2960 participants) and found that HRT II and HRT III had significant differences in stereometric parameters [62]. Several studies have also found that GPS is more likely than MRA to incorrectly classify large normal optic discs as abnormal [47-49, 60, 63-65]. Prior reports have suggested that within normal limits GPS classification is more useful than the MRA to confirm that a disc is normal; however, an outside normal limits MRA classification may be more useful than the GPS in confirming that a disc is not normal [65]. Prior studies suggest that GPS has a higher sensitivity and lower specificity than MRA in patients with mild glaucomatous visual field (VF) damage, but MRA better differentiates subjects with severe glaucomatous VF damage [60]. Alencar *et al.* recently showed that baseline GPS can be used to predict which glaucoma suspects will go on to display VF deterioration and optic disc change, the latter having a similar predictive value to expert evaluation of stereophotographs [66].

Table 1. Comparison of GPS vs MRA in prior studies.

Source	MRA Sensitivity (%)	GPS Sensitivity (%)	MRA Specificity (%)	GPS Specificity (%)
Reddy <i>et al.</i>	93	92	80.85	76.88
Yip <i>et al.</i>	67	71	71	67
Jindal <i>et al.</i>	98	73.47	98	34.69
Bozkurt <i>et al.</i>	81	89.2	75.0	57.6
Rao <i>et al.</i>	56.1-56.1*	86.7-93.9*	96.2-91.1*	68.3-39.2*
Saito <i>et al.</i>	39.4	65.2	96.1	83.0
Kamdeu Fansi <i>et al.</i>	77.3	85.7	64.3	78.7
Lee <i>et al.</i>	76-84*	80-96*	63.3-40*	60-40*

*Most specific to least specific criteria.

Specificity was affected by age and refraction in GPS. Coops *et al.* found a slight influence of age on specificity with MRA, but not with GPS [48]. Saito *et al.* demonstrated there was no influence of refraction on specificity with GPS [56], while Hawker *et al.* reported no influence of age on specificity with MRA [67].

With all these variables being taken into account, GPS is likely a better screening tool for the use of glaucoma than MRA due to a higher sensitivity and it is more user-friendly; however, this sensitivity may still not be enough when applied to population studies. The use of HRT in glaucoma screening and diagnosis has been thoroughly investigated previously, and we will explore these studies below.

THE USE OF HRT IN GLAUCOMA SCREENING AND DIAGNOSIS

It is estimated that between 50% and 90% of cases of glaucoma in the community are undiagnosed at any point in time [37, 68], so there has been interest in using the HRT as a screening device for glaucoma [15, 69-71]. Many studies have shown that HRT measurements are accurate and reproducible [31,72-74], more so than measurements from clinical examination.

The HRT is able to classify normal and glaucomatous eyes with at least as much accuracy as stereoscopic photographs evaluated by an experienced glaucoma specialist [75]. Andersson *et al.* compared the diagnostic accuracy of the HRT's MRA and GPS with that of subjective grading of optic disc photographs by 45 ophthalmologists. 97 glaucoma patients and 138 healthy patients participated [75]. Andersson found that while the sensitivity of MRA (75%) was superior to that of the average physician (60%), this did not apply to glaucoma experts. MRA had the best sensitivity in eyes with small optic discs.

The OHTS CSLO Ancillary Study found that baseline HRT stereometric parameters and indices were statistically significantly associated with the development of POAG in ocular hypertensive patients [76]. In multivariate models that controlled for age, IOP, PSD, central corneal thickness, history of heart disease and medication status, the overall, global, temporal inferior and nasal inferior MRA classification as outside normal limits were associated with an increase in POAG by 2.39, 3.37, 5.80, and 4.19, respectively. In patients with values outside the normal limits at baseline, the positive predictive value was found to be 14% by HRT classification, 14% by MRA overall, 18% by MRA nasal, 22% by MRA nasal inferior, 26% by MRA global, and 40% by MRA temporal superior. In contrast, the negative predictive value for the HRT classification for MRA was high at between 92-95%; these patients did not develop POAG in the follow-up period. In addition, there were no associations identified between HRT measurements and visual function, IOP, diabetes, systemic hypertension, or cardiovascular disease [27]. The study suggested that HRT indices that are consistently within the normal limits may be helpful in identifying ocular hypertensive patients that have a lower probability of developing glaucoma.

The HRT II was evaluated for its ability to be used as a screening tool for POAG in an older population by Healey *et al.* in a 10-year follow-up period from the Blue Mountains

Eye Study [77]. The MRA sensitivity was 64.1%, and specificity was 85.7%, with a positive predictive value of 21% and a negative predictive value of 97.6%. Healey found that when topography standard deviation was restricted to less than 40 μm , specificity was improved, but at the expense of sensitivity. However, it was concluded that this specificity was still not adequate for a glaucoma screening test.

The Singapore Malay Eye Study also evaluated the ability of the HRT II to diagnose glaucoma in a population setting in 124 glaucomatous eyes and 392 control eyes. The study found that the HRT II algorithms have limited usefulness in detecting glaucoma in Malay population given a moderate sensitivity (43.6%-71.0%) [78].

However, prior studies demonstrated the potential of HRT to be a useful glaucoma screening tool [79-82]. For example, one community-based study from Canada evaluated 303 high-risk individuals for glaucoma and found that the sensitivity of MRA was 84.3% with a specificity of 95.8% [81]. This was thought to be likely due to stricter exclusion criteria compared to studies that demonstrated HRT should not be used as a screening tool. In addition, some of these studies were not conducted in a randomly selected general population sample [79, 80].

HRT may be useful in monitoring progression in glaucoma [5, 72], though there is no consensus among the prior literature. One study suggested that TCA parameters can discriminate between progressing eyes and longitudinally observed healthy eyes [83]. However, another prospective study suggested that TCA progression criteria does not predict photographic or visual field progression [84]. Similarly, a retrospective study demonstrated that the stereometric parameters of the HRT did not have a high enough sensitivity and specificity to detect glaucomatous progression that was otherwise detected by photographs [85].

HRT COMPARED TO OCT

Optical coherence tomography (OCT) is a high-resolution, cross sectional imaging device that measures retinal thickness *in vivo* [86] and can also measure the RNFL thickness. The utilization of OCT in detecting glaucoma has also been studied and compared to the ability of HRT to detect glaucoma. One early study by Moreno-Montanes found that the sensitivity of RNFL damage detection using the HRT III was lower than compared to the Stratus OCT (Carl Zeiss International, Jena, Germany), especially in early glaucoma, with only fair RNFL thickness agreement between HRT III and OCT-3, suggesting that OCT has a higher diagnostic ability than HRT in detecting glaucoma [87].

A study by Lisboa *et al.* extended this hypothesis to glaucoma suspects and found that Spectral-Domain OCT (SD-OCT) performed better than HRT in detecting preperimetric glaucoma [88]. Another study demonstrated that SD-OCT not only had excellent intra- and interoperator repeatability of the RNFL measurements in POAG patients and POAG suspects, but also had a much lower measurement error than HRT III measurements with less variability of measurements [89]. Similarly, a study by Sato *et al.* also found poor agreement between the morphometric

measurements of the HRT III when compared with the SD-OCT, except for the cup-to-disc ratio [90].

There are several theories as to why the OCT may have a higher diagnostic ability than the HRT and may be a better clinical tool for glaucoma than HRT. The HRT estimates the RNFL thickness indirectly through the use of a reference plane, which assumes that the outer limit of the RNFL begins a certain depth that is arbitrarily set. The OCT, in contrast, measures the RNFL by identifying the amount of light reflected by it, as the RNFL is highly reflective. The OCT, in contrast to the HRT, has a slightly different normative database, which includes 205 Caucasian subjects, 79 Hispanic subjects, 27 African American subjects, and 11 Asian subjects [91]. In a prospective, cross-sectional study by Leung, diagnostic sensitivity of the HRT and the SD-OCT, which is a higher resolution OCT than the Stratus, were compared in 79 glaucoma patients and 76 controls and found that the Spectralis OCT (Heidelberg Engineering, Heidelberg, Germany) obtained a higher level [92].

Using OCT for RNFL measurements to aid in the diagnosis of glaucoma has been very popular [93, 94] in the past and indeed, will likely still be in the future.

CONCLUSION

Thus far, there is still no commercially available device or test that can differentiate perfectly between glaucomatous eyes and healthy eyes. While HRT data may be useful as a clinical adjunct in the screening and diagnosis of glaucoma, it should never be used alone to make a diagnosis of glaucoma, but rather, should only be used to support other clinical findings. Glaucoma ultimately remains a clinical diagnosis based on data from sources including optic disc tomography, VF testing, and careful examination of the patient and his or her history.

CONFLICT OF INTEREST

The authors confirm that this article content has no conflict of interest.

ACKNOWLEDGEMENTS

The authors would like to thank Alison Dowdell for editing and formatting support.

REFERENCES

- [1] Fingeret M, Flanagan JG, Liebmann JM, Eds. The essential HRT primer. San Ramon, CA: Jocoto Advertising 2005.
- [2] Zangwill LM, Weinreb RN, Berry CC, *et al*. Racial differences in optic disc topography: baseline results from the confocal scanning laser ophthalmoscopy ancillary study to the ocular hypertension treatment study. *Arch Ophthalmol* 2004; 122(1): 22-8.
- [3] Jonas JB, Gusek GC, Naumann GO. Optic disc, cup and neuroretinal rim size, configuration and correlations in normal eyes. *Invest Ophthalmol Vis Sci* 1988; 29: 1151-58.
- [4] Fingeret M, Medeiros FA, Susanna R Jr, Weinreb RN. Five rules to evaluate the optic disc and retinal nerve fiber layer for glaucoma. *Optometry* 2005; 76(11): 661-8.
- [5] Chauhan BC, McCormick TA, Nicolela MT, LeBlanc RP. Optic disc and visual field changes in a prospective longitudinal study of patients with glaucoma: comparison of scanning laser tomography with conventional perimetry and optic disc photography. *Arch Ophthalmol* 2001; 119(10): 1492-9.
- [6] Drance SM. The disc and the field in glaucoma. *Ophthalmology* 1978; 85(3): 209-14.
- [7] Hart WM Jr, Yablonski M, Kass MA, Becker B. Quantitative visual field and optic disc correlates early in glaucoma. *Arch Ophthalmol* 1978; 96(12): 2209-11.
- [8] Sommer A, Pollack I, Maumenee AE. Optic disc parameters and onset of glaucomatous field loss. II. Static screening criteria. *Arch Ophthalmol* 1979; 97(8): 1449-54.
- [9] Sommer A, Pollack I, Maumenee AE. Optic disc parameters and onset of glaucomatous field loss. I. Methods and progressive changes in disc morphology. *Arch Ophthalmol* 1979; 97(8): 1444-8.
- [10] Susanna R, Drance SM. Use of discriminant analysis I. Prediction of visual field defects from features of the glaucoma disc. *Arch Ophthalmol* 1978; 96(9): 1568-70.
- [11] Guthauser U, Flammer J, Niesel P. The relationship between the visual field and the optic nerve head in glaucomas. *Graefes Arch Clin Exp Ophthalmol* 1987; 225(2): 129-32.
- [12] Funk J, Bornscheuer C, Grehn F. Neuroretinal rim area and visual field in glaucoma. *Graefes Arch Clin Exp Ophthalmol* 1988; 226(5): 431-4.
- [13] Hyung SM, Kim DM, Youn DH. Optic disc and early glaucomatous visual field loss. *Korean J Ophthalmol* 1990; 4(2): 82-91.
- [14] Jonas JB, Grundler AE. Correlation between mean visual field loss and morphometric optic disk variables in the open-angle glaucomas. *Am J Ophthalmol* 1997; 124(4): 488-97.
- [15] Mikelberg FS, Parfitt CM, Swindale NV, Graham SL, Drance SM, Gosine R. Ability of the heidelberg retina tomograph to detect early glaucomatous visual field loss. *J Glaucoma* 1995; 4(4): 242-7.
- [16] Mardin CY, Horn FK, Jonas JB, Budde WM. Preperimetric glaucoma diagnosis by confocal scanning laser tomography of the optic disc. *Br J Ophthalmol* 1999; 83(3): 299-304.
- [17] Larrosa JM, Polo V, Ferreras A, Gil L, Fuertes I, Pablo LE. Predictive value of confocal scanning laser for the onset of visual field loss in glaucoma suspects. *Ophthalmology* 2012; 119(8): 1558-62.
- [18] Brigatti L, Caprioli J. Correlation of visual field with scanning confocal laser optic disc measurements in glaucoma. *Arch Ophthalmol* 1995; 113(9): 1191-4.
- [19] Lee KH, Park KH, Kim DM, Youn DH. Relationship between optic nerve head parameters of Heidelberg Retina Tomograph and visual field defects in primary open-angle glaucoma. *Korean J Ophthalmol* 1996; 10(1): 24-8.
- [20] Lester M, Mikelberg FS, Courtright P, Drance SM. Correlation between the visual field indices and Heidelberg retina tomograph parameters. *J Glaucoma* 1997; 6(2): 78-82.
- [21] Lester M, Mikelberg FS, Drance SM. The effect of optic disc size on diagnostic precision with the Heidelberg retina tomograph. *Ophthalmology* 1997; 104(3): 545-8.
- [22] Tole DM, Edwards MP, Davey KG, Menage MJ. The correlation of the visual field with scanning laser ophthalmoscope measurements in glaucoma. *Eye (Lond)* 1998; 12(Pt 4): 686-90.
- [23] Yamagishi N, Anton A, Sample PA, Zangwill L, Lopez A, Weinreb RN. Mapping structural damage of the optic disk to visual field defect in glaucoma. *Am J Ophthalmol* 1997; 123(5): 667-76.
- [24] Teesalu P, Vihanninjoki K, Airaksinen PJ, Tuulonen A, Laara E. Correlation of blue-on-yellow visual fields with scanning confocal laser optic disc measurements. *Invest Ophthalmol Vis Sci* 1997; 38(12): 2452-9.
- [25] Teesalu P, Vihanninjoki K, Airaksinen PJ, Tuulonen A. Hemifield association between blue-on-yellow visual field and optic nerve head topographic measurements. *Graefes Arch Clin Exp Ophthalmol* 1998; 236(5):339-45.
- [26] Chi T, Ritch R, Stickler D, Pitman B, Tsai C, Hsieh FY. Racial differences in optic nerve head parameters. *Arch Ophthalmol* 1989; 107(6): 836-9.
- [27] Zangwill LM, Weinreb RN, Berry CC, *et al*. The confocal scanning laser ophthalmoscopy ancillary study to the ocular hypertension treatment study: study design and baseline factors. *Am J Ophthalmol* 2004; 137(2): 219-27.
- [28] Girkin CA, McGwin G, Jr., Xie A, Deleon-Ortega J. Differences in optic disc topography between black and white normal subjects. *Ophthalmology* 2005; 112(1): 33-9.
- [29] Rohrschneider K, Burk RO, Kruse FE, Volcker HE. Reproducibility of the optic nerve head topography with a new

- laser tomographic scanning device. *Ophthalmology* 1994; 101(6): 1044-9.
- [30] Saarela V, Falck A, Airaksinen PJ, Tuulonen A. Factors affecting the sensitivity and specificity of the Heidelberg Retina Tomograph parameters to glaucomatous progression in disc photographs. *Acta Ophthalmol* 2012; 90(2): 132-8.
- [31] Chauhan BC, LeBlanc RP, McCormick TA, Rogers JB. Test-retest variability of topographic measurements with confocal scanning laser tomography in patients with glaucoma and control subjects. *Am J Ophthalmol* 1994; 118(1): 9-15.
- [32] Verdonck N, Zeyen T, Van Malderen L, Spileers W. Short-term intra-individual variability in heidelberg retina tomograph II. *Bull Soc Belge Ophtalmol* 2002; 286: 51-7.
- [33] Strouthidis NG, Garway-Heath DF. New developments in Heidelberg retina tomograph for glaucoma. *Curr Opin Ophthalmol* 2008; 19(2): 141-8.
- [34] Artes PH, Chauhan BC. Longitudinal changes in the visual field and optic disc in glaucoma. *Prog Retin Eye Res* 2005; 24(3): 333-54.
- [35] Betz P, Camps F, Collignon-Brach C, Weekers R. [Stereophotography and photogrammetry of the physiological cup of the disc (author's transl)]. *J Fr Ophtalmol* 1981; 4(3): 193-203.
- [36] Hoffmann EM, Miglier S, Zeyen T, *et al.* The Heidelberg retina tomograph ancillary study to the European glaucoma prevention study: study design and baseline factors. *Acta Ophthalmol* 2013; 91(8): e612-9.
- [37] Mitchell P, Smith W, Attebo K, Healey PR. Prevalence of open-angle glaucoma in Australia. The Blue Mountains Eye Study. *Ophthalmology* 1996; 103(10):1661-9.
- [38] Swindale NV, Stjepanovic G, Chin A, Mikelberg FS. Automated analysis of normal and glaucomatous optic nerve head topography images. *Invest Ophthalmol Vis Sci* 2000; 41(7): 1730-42.
- [39] Taibbi G, Fogagnolo P, Orzalesi N, Rossetti L. Reproducibility of the heidelberg Retina Tomograph III glaucoma probability score. *J Glaucoma* 2009; 18(3): 247-52.
- [40] Prata TS, Meira-Freitas D, Lima VC, Guedes LM, Magalhaes FP, Paranhos A Jr. Factors affecting the variability of the Heidelberg Retina Tomograph III measurements in newly diagnosed glaucoma patients. *Arq Bras Oftalmol* 2010; 73(4): 354-7.
- [41] Pablo LE, Ferreras A, Fogagnolo P, Figus M, Pajarin AB. Optic nerve head changes in early glaucoma: a comparison between stereophotography and Heidelberg retina tomography. *Eye* 2010; 24: 123-30.
- [42] Bowd C, Zangwill LM, Medeiros FA, *et al.* Confocal scanning laser ophthalmoscopy classifiers and stereophotograph evaluation for prediction of visual field abnormalities in glaucoma-suspect eyes. *Invest Ophthalmol Vis Sci* 2004; 45(7): 2255-62.
- [43] Deleon-Ortega JE, Arthur SN, McGwin G Jr, Xie A, Monheit BE, Girkin CA. Discrimination between glaucomatous and nonglaucomatous eyes using quantitative imaging devices and subjective optic nerve head assessment. *Invest Ophthalmol Vis Sci* 2006; 47(8): 3374-80.
- [44] Medeiros FA, Zangwill LM, Bowd C, Vasile C, Sample PA, Weinreb RN. Agreement between stereophotographic and confocal scanning laser ophthalmoscopy measurements of cup/disc ratio: effect on a predictive model for glaucoma development. *J Glaucoma* 2007; 16(2): 209-14.
- [45] Sihota R, Gulati V, Agarwal HC, Saxena R, Sharma A, Pandey RM. Variables affecting test-retest variability of Heidelberg Retina Tomograph II stereometric parameters. *J Glaucoma* 2002; 11(4): 321-8.
- [46] Strouthidis NG, Demirel S, Asaoka R, Cossio-Zuniga C, Garway-Heath DF. The Heidelberg retina tomograph Glaucoma Probability Score: reproducibility and measurement of progression. *Ophthalmology* 2010; 117(4): 724-9.
- [47] Harizman N, Zelefsky JR, Ilitchev E, Tello C, Ritch R, Liebmann JM. Detection of glaucoma using operator-dependent versus operator-independent classification in the Heidelberg retinal tomograph-III. *Br J Ophthalmol* 2006; 90(11): 1390-2.
- [48] Coops A, Henson DB, Kwartz AJ, Artes PH. Automated analysis of heidelberg retina tomograph optic disc images by glaucoma probability score. *Invest Ophthalmol Vis Sci* 2006; 47(12): 5348-55.
- [49] Burgansky-Eliash Z, Wollstein G, Bilonick RA, Ishikawa H, Kagemann L, Schuman JS. Glaucoma detection with the Heidelberg retina tomograph 3. *Ophthalmology* 2007; 114(3): 466-71.
- [50] Zelefsky JR, Harizman N, Mora R, *et al.* Assessment of a race-specific normative HRT-III database to differentiate glaucomatous from normal eyes. *J Glaucoma* 2006; 15(6): 548-51.
- [51] Reddy S, Xing D, Arthur SN, *et al.* HRT III glaucoma probability score and Moorfields regression across the glaucoma spectrum. *J Glaucoma* 2009; 18(5): 368-72.
- [52] Yip LW, Mikelberg FS. A comparison of the glaucoma probability score to earlier heidelberg retina tomograph data analysis tools in classifying normal and glaucoma patients. *J Glaucoma* 2008; 17(7): 513-6.
- [53] Jindal S, Dada T, Sreenivas V, Gupta V, Sihota R, Panda A. Comparison of the diagnostic ability of Moorfield's regression analysis and glaucoma probability score using Heidelberg retinal tomograph III in eyes with primary open angle glaucoma. *Indian J Ophthalmol* 2010; 58(6): 487-92.
- [54] Bozkurt B, Ircek M, Arslan U. Diagnostic accuracy of Heidelberg Retina Tomograph III classifications in a Turkish primary open-angle glaucoma population. *Acta Ophthalmol* 2010; 88(1): 125-30.
- [55] Rao HL, Babu GJ, Sekhar GC. Comparison of the diagnostic capability of the Heidelberg Retina Tomographs 2 and 3 for glaucoma in the Indian population. *Ophthalmology* 2010; 117(2): 275-81.
- [56] Saito H, Tomidokoro A, Yanagisawa M, Iwase A, Araie M. Sensitivity and specificity with the glaucoma probability score in Heidelberg Retina Tomograph II in Japanese eyes. *J Glaucoma* 2009; 18(3): 227-32.
- [57] Kamdeu Fansi AA, Agoumi Y, Harasymowycz PJ. Screening for glaucoma with Moorfields regression analysis and glaucoma probability score in confocal scanning laser ophthalmoscopy. *Can J Ophthalmol* 2011; 46(3): 254-60.
- [58] Lee JM, Cirineo N, Ramanathan M, *et al.* Performance of the visual field index in glaucoma patients with moderately advanced visual field loss. *Am J Ophthalmol* 2014; 157(1): 39-43.
- [59] Saito H, Tsutsumi T, Araie M, Tomidokoro A, Iwase A. Sensitivity and specificity of the Heidelberg Retina Tomograph II Version 3.0 in a population-based study: the Tajimi Study. *Ophthalmology* 2009; 116(10): 1854-61.
- [60] Ferreras A, Pajarin AB, Polo V, Larrosa JM, Pablo LE, Honrubia FM. Diagnostic ability of Heidelberg Retina Tomograph 3 classifications: glaucoma probability score versus Moorfields regression analysis. *Ophthalmology* 2007; 114(11): 1981-7.
- [61] Moreno-Montanes J, Anton A, Garcia N, Mendiluce L, Ayala E, Sebastian A. Glaucoma probability score vs Moorfields classification in normal, ocular hypertensive, and glaucomatous eyes. *Am J Ophthalmol* 2008; 145(2): 360-8.
- [62] Koh V, Loon SC, Wong WL, Wong TY, Aung T. Comparing stereometric parameters between Heidelberg Retinal Tomography 2 and 3 in Asian eyes: the Singapore Malay Eye Study. *J Glaucoma* 2012; 21(2): 102-6.
- [63] De Leon-Ortega JE, Sakata LM, Monheit BE, McGwin G, Jr., Arthur SN, Girkin CA. Comparison of diagnostic accuracy of Heidelberg Retina Tomograph II and Heidelberg Retina Tomograph 3 to discriminate glaucomatous and nonglaucomatous eyes. *Am J Ophthalmol* 2007; 144(4): 525-32.
- [64] Oddone F, Centofanti M, Rossetti L, *et al.* Exploring the Heidelberg Retinal Tomograph 3 diagnostic accuracy across disc sizes and glaucoma stages: a multicenter study. *Ophthalmology* 2008; 115(8): 1358-65, 65 e1-3.
- [65] Zangwill LM, Jain S, Racette L, *et al.* The effect of disc size and severity of disease on the diagnostic accuracy of the Heidelberg Retina Tomograph Glaucoma Probability Score. *Invest Ophthalmol Vis Sci* 2007; 48(6): 2653-60.
- [66] Alencar LM, Bowd C, Weinreb RN, Zangwill LM, Sample PA, Medeiros FA. Comparison of HRT-3 glaucoma probability score and subjective stereophotograph assessment for prediction of progression in glaucoma. *Invest Ophthalmol Vis Sci* 2008; 49(5): 1898-906.
- [67] Hawker MJ, Vernon SA, Ainsworth G. Specificity of the Heidelberg Retina Tomograph's diagnostic algorithms in a normal elderly population: the Bridlington Eye Assessment Project. *Ophthalmology* 2006; 113(5): 778-85.
- [68] Shen SY, Wong TY, Foster PJ, *et al.* The prevalence and types of glaucoma in malay people: the Singapore Malay eye study. *Invest Ophthalmol Vis Sci* 2008; 49(9): 3846-51.

- [69] Uchida H, Brigatti L, Caprioli J. Detection of structural damage from glaucoma with confocal laser image analysis. *Invest Ophthalmol Vis Sci* 1996; 37(12): 2393-401.
- [70] Caprioli J, Park HJ, Ugurlu S, Hoffman D. Slope of the peripapillary nerve fiber layer surface in glaucoma. *Invest Ophthalmol Vis Sci* 1998; 39(12): 2321-8.
- [71] Bathija R, Zangwill L, Berry CC, Sample PA, Weinreb RN. Detection of early glaucomatous structural damage with confocal scanning laser tomography. *J Glaucoma* 1998; 7(2): 121-7.
- [72] Dreher AW, Weinreb RN. Accuracy of topographic measurements in a model eye with the laser tomographic scanner. *Invest Ophthalmol Vis Sci* 1991; 32(11): 2992-6.
- [73] Cioffi GA, Robin AL, Eastman RD, Perell HF, Sarfarazi FA, Kelman SE. Confocal laser scanning ophthalmoscope. Reproducibility of optic nerve head topographic measurements with the confocal laser scanning ophthalmoscope. *Ophthalmology* 1993; 100(1): 57-62.
- [74] Weinreb RN, Lusky M, Bartsch DU, Morsman D. Effect of repetitive imaging on topographic measurements of the optic nerve head. *Arch Ophthalmol* 1993; 111(5): 636-8.
- [75] Andersson S, Heijl A, Bengtsson B. Optic disc classification by the Heidelberg Retina Tomograph and by physicians with varying experience of glaucoma. *Eye (Lond)* 2011; 25(11): 1401-7.
- [76] Zangwill LM, Weinreb RN, Beiser JA, *et al.* Baseline topographic optic disc measurements are associated with the development of primary open-angle glaucoma: the Confocal Scanning Laser Ophthalmoscopy Ancillary Study to the Ocular Hypertension Treatment Study. *Arch Ophthalmol* 2005; 123(9): 1188-97.
- [77] Healey PR, Lee AJ, Aung T, Wong TY, Mitchell P. Diagnostic accuracy of the Heidelberg Retina Tomograph for glaucoma a population-based assessment. *Ophthalmology* 2010; 117(9): 1667-73.
- [78] Zheng Y, Wong TY, Lamoureux E, *et al.* Diagnostic ability of Heidelberg Retina Tomography in detecting glaucoma in a population setting: the Singapore Malay Eye Study. *Ophthalmology* 2010; 117(2): 290-7.
- [79] Harasymowycz PJ, Papamtheakis DG, Fanni AK, Gresset J, Lesk MR. Validity of screening for glaucomatous optic nerve damage using confocal scanning laser ophthalmoscopy (Heidelberg Retina Tomograph II) in high-risk populations: a pilot study. *Ophthalmology* 2005; 112(12): 2164-71.
- [80] Ohkubo S, Takeda H, Higashide T, Sasaki T, Sugiyama K. A pilot study to detect glaucoma with confocal scanning laser ophthalmoscopy compared with nonmydriatic stereoscopic photography in a community health screening. *J Glaucoma* 2007; 16(6): 531-8.
- [81] Wollstein G, Garway-Heath DF, Fontana L, Hitchings RA. Identifying early glaucomatous changes. Comparison between expert clinical assessment of optic disc photographs and confocal scanning ophthalmoscopy. *Ophthalmology* 2000; 107(12): 2272-7.
- [82] Garway-Heath DF, Hitchings RA. Quantitative evaluation of the optic nerve head in early glaucoma. *Br J Ophthalmol* 1998; 82(4): 352-61.
- [83] Bowd C, Balasubramanian M, Weinreb RN, *et al.* Performance of confocal scanning laser tomograph Topographic Change Analysis (TCA) for assessing glaucomatous progression. *Invest Ophthalmol Vis Sci* 2009; 50(2): 691-701.
- [84] Kourkoutas D, Buys YM, Flanagan JG, *et al.* Clinical significance of optic disc progression by topographic change analysis maps in glaucoma: an 8-year follow-up study. *J Ophthalmol* 2014; 2014: 987389.
- [85] Saarela V, Falck A, Airaksinen PJ, Tuulonen A. The sensitivity and specificity of Heidelberg Retina Tomograph parameters to glaucomatous progression in disc photographs. *Br J Ophthalmol* 2010; 94(1): 68-73.
- [86] Hee MR, Izatt JA, Swanson EA, *et al.* Optical coherence tomography of the human retina. *Arch Ophthalmol* 1995; 113(3): 325-32.
- [87] Moreno-Montanes J, Anton A, Garcia N, Olmo N, Morilla A, Fallon M. Comparison of retinal nerve fiber layer thickness values using Stratus Optical Coherence Tomography and Heidelberg Retina Tomograph-III. *J Glaucoma* 2009; 18(7): 528-34.
- [88] Lisboa R, Leite MT, Zangwill LM, Tafreshi A, Weinreb RN, Medeiros FA. Diagnosing preperimetric glaucoma with spectral domain optical coherence tomography. *Ophthalmology* 2012; 119(11): 2261-9.
- [89] Shpak AA, Sevostyanova MK, Ogorodnikova SN, Shormaz IN. Comparison of measurement error of Cirrus HD-OCT and Heidelberg Retina Tomograph 3 in patients with early glaucomatous visual field defect. *Graefes Arch Clin Exp Ophthalmol* 2012; 250(2): 271-7.
- [90] Sato S, Hirooka K, Baba T, Shiraga F. Comparison of optic nerve head parameters using Heidelberg Retina Tomograph 3 and spectral-domain optical coherence tomography. *Clin Experiment Ophthalmol* 2012; 40(7): 721-6.
- [91] Patella VM. STRATUSOCT: Establishment of Normative Reference Values for Retinal Nerve Fiber Layer Thickness Measurements 2003: Available from: [http://www.zeiss.co.nz/C1256C4F002FF302/EmbedTitelIntern/StratusOCT/\\$File/OCT+Normative+Database+Paper.pdf](http://www.zeiss.co.nz/C1256C4F002FF302/EmbedTitelIntern/StratusOCT/$File/OCT+Normative+Database+Paper.pdf).
- [92] Leung CK, Ye C, Weinreb RN, *et al.* Retinal nerve fiber layer imaging with spectral-domain optical coherence tomography: a study on diagnostic agreement with heidelberg retinal tomograph. *Ophthalmology* 2010; 117: 267-74.
- [93] Jaffe GJ, Caprioli J. Optical coherence tomography to detect and manage retinal disease and glaucoma. *Am J Ophthalmol* 2004; 137(1): 156-69.
- [94] Savini G, Bellusci C, Carbonelli M, *et al.* Detection and quantification of retinal nerve fiber layer thickness in optic disc edema using stratus OCT. *Arch Ophthalmol* 2006; 124(8): 1111-7.

Received: March 28, 2015

Revised: March 30, 2015

Accepted: March 30, 2015

© Maslin *et al.*; Licensee Bentham Open.

This is an open access article licensed under the terms of the Creative Commons Attribution Non-Commercial License (<http://creativecommons.org/licenses/by-nc/3.0/>) which permits unrestricted, non-commercial use, distribution and reproduction in any medium, provided the work is properly cited.